

LETTERS TO THE EDITOR

The first study on combined carboxytherapy and minoxidil 20% in the treatment of Lichen planopilaris: A case series and literature review

To the Editor,

LP is an inflammatory clinical condition affecting hair, nails, and mucosal membranes. Lichen planopilaris is a rare variant of LP involving hair follicles and causes primary cicatricial alopecia. The course of hair loss in LPP is sudden onset accompanying by itching, burning, and scalp pain. During the active phase of the disease, scalp scarring is presented due to inflammation.¹ The main goal of LPP treatment is to prevent hair loss and scar formation. Most systemic treatments

present unfavorable adverse effects such as immunosuppression that limit their use; hence, localized treatment can play an essential role. Carboxytherapy has frequently been used for cosmetic and therapeutic purposes in recent years.^{2,3} Carbon dioxide (CO₂) induced hypercapnia and decreased pH increase blood supply and oxygen transportation to the site of injection.⁴ The promising effects of carboxytherapy, especially in patients with alopecia, prompted us to the current study. In this study, nine patients (20–50) with

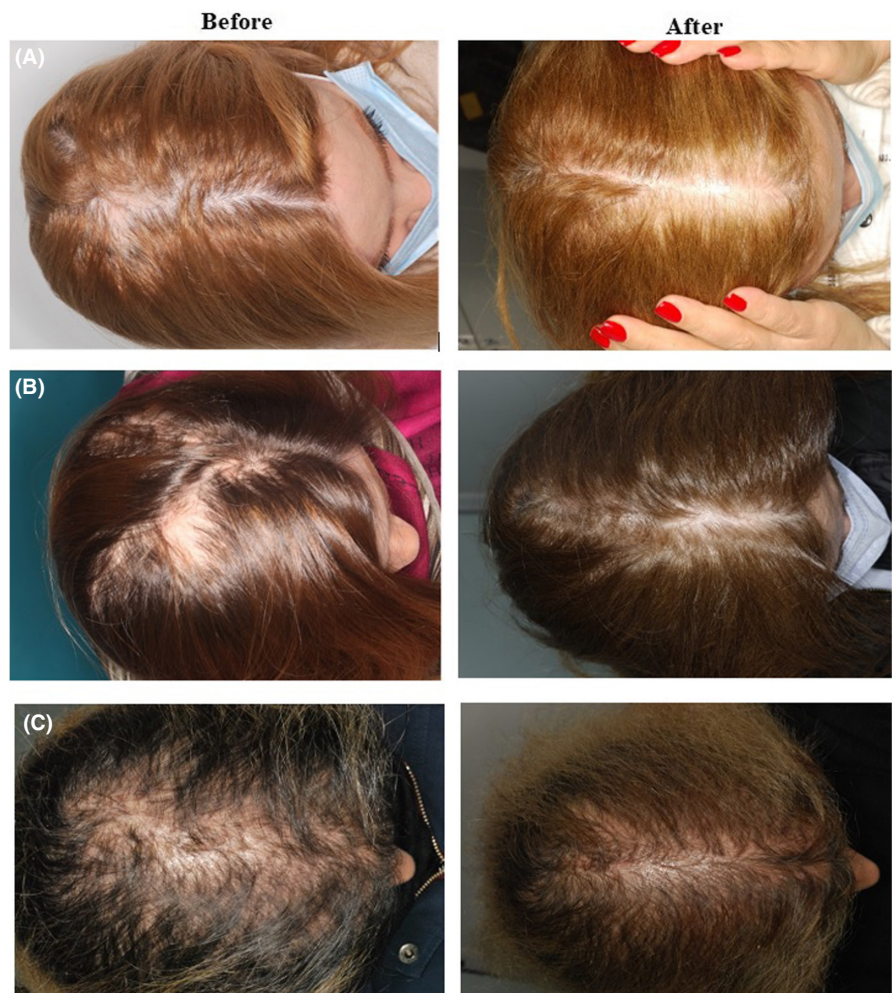

FIGURE 1 Study patients: Patient A with an alopecia patch on the top of the scalp progressing to the crown, patient B with an alopecia patch on the top of the scalp and another patch on the left side of the scalp and patient C with scattered alopecia areas from frontal to the crown before the treatment and 12 months after the treatment

TABLE 1 Signs, symptoms, and LPPAI in the patients before and after the combination therapy

ID	Age	A b/a	B b/a	C b/a	D b/a	E b/a	F b/a	G b/a	H b/a	Medication	LPPAI
1	41	2/0	3/1	3/1	2/1	2/1	3/1	1/0	1/0	HXC twice daily	8.24
2	37	2/0	2/1	2/1	2/0	2/0	1/0	1/0	1/0	HXC + prednisolone	7.58
3	44	2/0	2/0	2/0	3/1	3/1	1/0	1/0	1/0	HXC + prednisolone	8.58
4	28	1/0	3/1	3/1	2/1	2/1	2/1	1/0	1/0	HXC twice daily	7.58
5	48	1/0	3/0	3/0	2/0	2/0	1/1	1/0	1/0	HXC + prednisolone	7.24
6	38	1/0	3/1	3/1	2/0	2/0	1/0	1/0	1/0	HXC twice daily + prednisolone twice daily	7.25
7	42	1/0	3/1	3/1	3/1	3/1	2/0	1/0	1/0	HXC twice daily	8.24
8	48	1/0	3/1	3/1	2/0	2/0	2/1	1/0	1/0	HXC twice daily	7.58
9	34	1/0	3/1	3/1	2/0	2/0	2/1	1/0	1/0	HXC + prednisolone	7.58

Note: A: Pain, B: Burning, C: Itching, D: Scalp Erythema, E: Perifollicular Erythema, F: Perifollicular Scaling, G: Spreading, H: Hair-pull Test. Abbreviations: a, after; b, before.

cicatricial alopecia resulted from chronic Lichen planopilaris were enrolled. All patients had patch-like alopecia that were not extensive, and they all were in the moderate stage of LPP, resistant to the first line of LPP treatment. Patients received Carboxytherapy every 2 weeks (three total sessions), and topical Minoxidil 20% per month for a total of three consecutive months. Hair-pull test, dermoscopy, and photography were performed to record the treatment's results before and every 3 months after treatment for 1 year. One year after the combination therapy, the results of hair-pull test significantly decreased in all nine patients. The post-treatment assessment showed a significant increase in the hair density and diameter. The photographs of three patients are displayed before and 12 months after the treatment (Figure 1). The LPPAI score ranges is shown in Table 1 and indicating the decrease of LPPAI after treatment ($p < 0.01$). To the best of our knowledge, this is the first study to assess the efficacy of the combination of carboxytherapy and Minoxidil 20% in the treatment of Primary cicatricial alopecia resulted from LPP. Our results showed that carboxytherapy combined with minoxidil 20% significantly remitted LPP, and the remission is proved by biopsy 1 year after the treatment. The treatment decreased the perifollicular erythema and scaling, and hair-pull test. Additionally, hair density and diameter in all patients significantly increased. Some recent studies are looking for non-systemic treatments to prevent general adverse effects resulting from common medications in LPP such as cyclosporine and prednisolone. Among all the novel treatments for PCA and LPP, carboxytherapy is one of the most resultful, cost-effective methods, and has a favorable safety profile. The primary mechanism of carboxytherapy is explained with the Verigo-Bohr effect, wherein rising CO_2 in tissues causes hypercapnia and acidosis in hemoglobin (Hb) molecules that induce O_2 release from Hb and increase ventilation.⁵ Another major CO_2 mechanism of action is the direct influence on vessels, causing vasodilation and increasing blood flow to the injection site. In this mechanism, local angiogenic growth factors such as Venous Endothelial Growth Factor (VEGF) and Fibroblasts Growth Factor (FGF) are released, causing further circulation increase, lipolysis, lymph drainage, and dermal

regeneration.⁶ Moreover, CO_2 causes a reflex stimulation of respiratory and vasomotor centers of the medulla oblongata⁷; all these actions ultimately result in enhancing synthesis, turnover, deposition, and reorganization of collagen in the skin, that eventually improve skin remodeling, self-healing, texture, and tone.⁸ Adverse effects following carboxytherapy were not serious and primarily included self-limiting bruising, small hematoma, and mild to moderate pain and burning at the site of injection. Briefly, Carboxytherapy can be a potential treatment for LPP-induced alopecia due to stimulating angiogenic growth factors production, increasing blood flow to the injection site and collagen remodeling.

AUTHOR CONTRIBUTIONS

N. MA, G. A, B. E, and R. M, performed the research. N. MA designed the research study. H-K.M analyzed the data. T. E, S. S, and S. F collected the data.

ACKNOWLEDGMENTS

The authors would like to express their gratitude to the Skin and Stem Cell Research Center at Tehran University of Medical Sciences, colleagues and staff in Jordan Clinic, Tehran University of Medical Sciences, Tehran, Iran, and to the authorities of Rasool Akram Medical Complex Clinical Research Development Center (RCRDC), Iran University of Medical Sciences for their technical and editorial assistance.

FUNDING INFORMATION

The Skin and Stem Cell Research Center at Tehran University of Medical Sciences, Tehran, Iran.

CONFLICT OF INTEREST

The authors declare no conflicts of interest.

DATA AVAILABILITY STATEMENT

The data that support the findings of this study are available from the corresponding author upon reasonable request.

ETHICAL APPROVAL

The authors state that the patients have given their informed consent for contribution in the study, photographs, and all details.


Mohammad Ali Nilforoushzadeh MD^{1,2} 

Maryam Heidari-Kharaji PhD^{1,2,3} 


Elham Torkamaniha PhD^{1,2,4} 

Sara Sadeghi MD^{1,5} 

Farnoosh Seirafianpour MD⁶ 

Mir Saeed Yekaninejad PhD⁷ 

Elham Behrangi MD^{1,8} 

Masoumeh Roohaninasab MD^{1,8} 

Zeynab Amini PhD⁹

Azadeh Goodarzi MD^{8,1} 

¹Skin & Stem Cell Research Center, Tehran University of Medical Sciences, Tehran, Iran

²Jordan Dermatology & Hair Transplantation Center, Tehran, Iran

³Institut National de la Recherche Scientifique (INRS)-Centre Armand-Frappier Santé Biotechnologie (CAFSB), Laval, QC, Canada

⁴Department of Microbial Biotechnology, Islamic Azad University, Kish Branch, Iran

⁵Rasool Akram Medical Complex Clinical Research Development Center (RCRDC), Iran University of Medical Sciences, Tehran, Iran

⁶Student Research Committee, School of Medicine, Iran University of Medical Sciences, Tehran, Iran

⁷Department of Epidemiology & Biostatistics, School of Public Health, Tehran University of Medical Sciences, Tehran, Iran

⁸Department of Dermatology, Rasool Akram Medical Complex Clinical Research Development Center (RCRDC), School of Medicine, Iran University of Medical Sciences, Tehran, Iran

⁹School of Biology and Environmental Science, Queensland University of Technology, Brisbane, Qld, Australia

Correspondence

Azadeh Goodarzi, Department of Dermatology, Rasool Akram Medical Complex Clinical Research Development Center (RCRDC), School of Medicine, Iran University of

Medical Sciences, Tehran, Iran.

Email: azadeh_goodarzi1984@yahoo.com; goodarzi.a@iums.ac.ir

Elham Torkamaniha, Skin & Stem Cell Research Center, Tehran University of Medical Sciences, Tehran, Iran.

Email: elham.torkamaniha@gmail.com

ORCID

Mohammad Ali Nilforoushzadeh  <https://orcid.org/0000-0001-6143-8039>

[org/0000-0001-6143-8039](https://orcid.org/0000-0001-6143-8039)

Maryam Heidari-Kharaji  <https://orcid.org/0000-0001-6954-7942>

Elham Torkamaniha  <https://orcid.org/0000-0003-3116-3163>

Sara Sadeghi  <https://orcid.org/0000-0002-1657-1487>

Farnoosh Seirafianpour  <https://orcid.org/0000-0003-3794-6206>

Mir Saeed Yekaninejad  <https://orcid.org/0000-0003-3648-5276>

Elham Behrangi  <https://orcid.org/0000-0002-6545-3460>

Masoumeh Roohaninasab  <https://orcid.org/0000-0002-2862-6422>

Azadeh Goodarzi  <https://orcid.org/0000-0002-1249-4429>

REFERENCES

1. Ianoşi SL, Forsea AM, Lupu M, et al. Role of modern imaging techniques for the in vivo diagnosis of lichen planus. *Exp Ther Med*. 2019;17(2):1052-1060.
2. Doghaim NN, el-Tatawy RA, Neinaa YMEH, Abd el-samd MM. Study of the efficacy of carboxytherapy in alopecia. *J Cosmet Dermatol*. 2018;17(6):1275-1285.
3. Nilforoushzadeh MA, Lotfi E, Heidari-Kharaji M, Zolghadr S, Mansouri P. Effective combination therapy with high concentration of minoxidil and Carboxygas in resistant androgenetic alopecia: report of nine cases. *J Cosmet Dermatol*. 2020;19(11):2953-2957.
4. Metwally D, Abdel-Fattah R, Hilal RF. Comparative study for treatment of alopecia areata using carboxy therapy, intralesional corticosteroids, and a combination of both. *Arch Dermatol Res*. 2021;314:167-182.
5. Bunyatyan N, Drogovoz SM, Shtroblya AL, et al. The mechanism of the pulmprotective action of carboxytherapy. *Vopr Kurortol Fizioter Lech Fiz Kult*. 2019;96(4):58-62.
6. Ferreira LM, Silva EK, Jaimovich CA, et al. Carboxytherapy: seeking evidence for its use in plastic surgery and dermatology. *Rev Bras Cir Plást*. 2012;27:350-351.
7. Drogovoz, S., Tkachenko, Y.P., Abdurakhmonov, J. Mechanisms of action carboxytherapy. 2015.
8. Brochado T, Schweich LC, Pietro Simoes N, Oliveira RJ, Antonioli-Silva ACM. Carboxytherapy: controls the inflammation and enhances the production of fibronectin on wound healing under venous insufficiency. *Int Wound J*. 2018;16:316-324.