

CASE REPORT

The first case report of Haim Munk disease with neurological manifestations and literature review

Mehdi Moghaddasi¹ | Mohammadreza Ghassemi² | Mohammad Shekari Yazdi² |
Seyed Amir Hasan Habibi¹ | Nafiseh Mohebi¹ | Azadeh Goodarzi² 

¹Department of Neurology, Rasool Akram Medical Complex, Iran University of Medical Sciences (IUMS), Tehran, Iran

²Department of Dermatology, Rasool Akram Medical Complex, Iran University of Medical Sciences (IUMS), Tehran, Iran

Correspondence

Azadeh Goodarzi and Mohammad Shekari Yazdi, Department of Dermatology, Rasool Akram Medical Complex, Iran University of Medical Sciences (IUMS), Tehran, Iran.
Email: goodarzi.a@iums.ac.ir; azadeh_goodarzi1984@yahoo.com (AG); mshekariyazdi@gmail.com (MSY)

Funding information

None

Abstract

HMS can have neurologic MS like manifestations. It is urgent to do more research and report probable unknown associations of HMS for its better management.

KEYWORDS

demyelinating disease, Haim-Munk syndrome, palmoplantar keratoderma, Papillon-Lefevre syndrome, periodontitis

1 | INTRODUCTION

Papillon-Lefevre syndrome and its phenotypic variant, Haim-Munk syndrome, are syndromic palmoplantar keratodermas. This is the first report of neurologic manifestations of MS in a known case of HMS. The patient was treated with methyl prednisolone pulse therapy with a cumulative dose of 5 grams.

Papillon-Lefevre syndrome (PLS) is an autosomal recessive syndromic generalized palmoplantar keratoderma (PPK). It was first described by Papillon MM and Lefevre

P in 1924.¹ Its prevalence is 1–4 per million and has no gender predilection.^{2,3} Clinically it has a transgradient PPK. PLS patients have a loss of function mutation in cathepsin C gene (CTSC). Cathepsins could be Cysteine, Serine or Aspartic. Cathepsin C belongs to Cysteine type cathepsins.⁴ CTSC mutation leads to periodontitis and patients lose their teeth during childhood and later lose their permanent teeth.⁵ They can have pseudoainhum and psoriasiform plaques and are predisposed to pyogenic infections. Haim-Munk syndrome (HMS), first described by Haim and Munk in 1965,⁶ is the phenotypic variant of

Mehdi Moghaddasi and Mohammadreza Ghassemi equally contributed to this work and are first author.

This is an open access article under the terms of the Creative Commons Attribution License, which permits use, distribution and reproduction in any medium, provided the original work is properly cited.

© 2021 The Authors. *Clinical Case Reports* published by John Wiley & Sons Ltd.

PLS with the CTSC gene mutation.⁷ Haim-Munk characteristic signs are onychogryphosis, arachnodactyly, acroosteolysis, flat foot and permanent flexion contractures.⁸

Periodontitis in Papillon-Lefèvre syndrome and Haim-Munk syndrome arises from a failure to eliminate periodontal pathogens because of cathepsin C deficiency. Recruitment and accumulation of hyperactive/reactive neutrophils and a reduced antimicrobial capacity lead to a locally destructive chronic inflammatory cycle in Papillon-Lefèvre syndrome and Haim-Munk syndrome.⁹ There has been some improvement in impaired autophagy, caused by insufficient lysosomal function, after introducing cathepsin C in fibroblast cell culture.¹⁰ Haim-Munk syndrome (HMS) could also be erythrodermic or be accompanied with destructive arthritis.^{11,12} Retinoids such as acitretin, topical keratolytics, antibiotics for oral and pyogenic infections and dental care can be used as treatment for PLS and HMS.¹³ A tabular literature review of PLS treatment can be found in Tambe L, Dixit M, Patil N. literature review.¹⁴

1.1 | Neurologic manifestations

Mental retardation and psychotic depression have been reported in PLS.¹⁵ Dural and choroid plexus calcifications are also found in patients with PLS.⁸ There is a report of convulsion due to multiple cerebral abscesses.¹⁶ Finally, there have been reports of abdominal epilepsy in a patient with PLS.¹⁷

We were unable to find any neurological manifestations of Haim-Munk syndrome in peer-reviewed literature.

2 | CASE REPORT

The patient is a 42-year-old married Muslim man from Ardakan, a province of the city Yazd, in Iran. He has one healthy daughter and comes from a middle-class background. From early infancy, when he was 6 months old, he has been suffering from transgradient PPK. He lost his deciduous and later his permanent teeth. At the age of 15, he lost all of his teeth, and hence became edentulous. At the same time, he suffered PPK with the hyperkeratosis of elbows and knees. His pathology report from 2009 shows hyperkeratosis, acanthosis and perivascular lymphohistiocytic infiltrate in upper and mid dermis, compatible with PLS hyperkeratotic skin lesions.

He is a first-born child and has two siblings; one sister and one brother. His siblings are healthy and have no sign of PPK. His parents were first-degree cousins. His father died from brain tumor and his mother suffers from

seizures and is on anticonvulsive and antidepressant medications. Neither his parents nor his siblings suffered from PPK.

At the age of 15 the patient began receiving corticosteroids and Neotigason. Due to the development of arthralgia and bone pain, his physician decreased the dose of Neotigason. For the past years, he has been on Roaccutane 20 mg fort wo to three times a week and has had stable skin lesions.

In dermatologic examination, the patient had transgradient PPK with knee and elbow involvement. He also suffered from flexion contracture of toes, onychogryphosis, and arachnodactyly, all of which are characteristics of Haim-Munk syndrome.

2.1 | Neurologic manifestations

His present illness began in January 2020 when he developed fever, malaise and sleepiness. Additionally, he developed right-sided weakness that improved spontaneously after a week. The exact same episode repeated itself 8 months later in mid-September of 2020. Again, his condition improved spontaneously. Furthermore, the patient complained from tiredness after walking in the prior 2-3 months.

After the last episode in September 2020, the patient was admitted to the neurology ward of Rasul-e-Akram hospital in Tehran, Iran. In his neurologic examination, he had spastic gait with a wide base, increased deep tendon reflexes (DTR), upward plantar reflexes and bilateral dysmetric finger to nose tests. Ophthalmologic exam was normal.

Laboratory tests, including acute phase reactants and viral markers, were unremarkable. Serum NMO and MoG Ab were negative. CSF fluid analysis was normal as well. A positive oligoclonal band test was performed with a delay, which confirmed the diagnosis.

Brain MRI showed multiple bilateral non-enhancing hypersignal lesions mostly in periventricular, subcortical, juxtacortical, infratentorial (pons and cerebellar peduncles) regions in T2 and FLAIR sequences. In cervical MRI, C1-C2 and C2-C4 levels had multiple T2 and STIR hyperintense patchy foci without enhancement.

According to the MRI findings, with an impression of demyelinating disease, he received methyl prednisolone pulse therapy with a cumulative dose of 5 gr.

Additionally, he suffered from depression and irritability and hurt himself by banging his head when he was angry.

After discharge the patient has been put on pantoprazole 40 mg QD, Vit B1 300 mg QD, Tab Ca-D QD, Pearl Vit

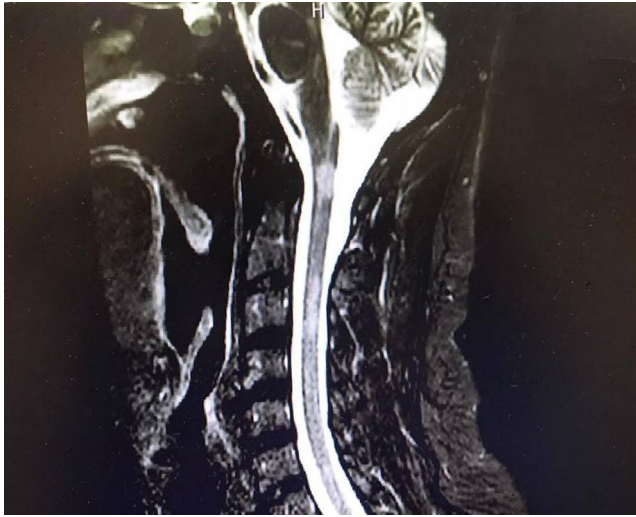

FIGURE 1 T2-STIR cervical MRI shows multiple bright lesions compatible with demyelinating disease (multiple sclerosis)

D3 50000 U weekly, Tab Hydroxychloroquine 200 mg QD, Tab Roaccutane 20 mg twice weekly and Eucerin + urea 5% cream. Figures 1-6 show neurological and dermatological manifestation of the reported case.

3 | DISCUSSION

In addition to periodontitis and PPK, HMS has arachnodactyly, acro-osteolysis, atrophic changes of the nails (and in some sources onychogryphosis), and a radiographic deformity of the fingers. Additionally, some regard flat foot (Pes Planus) as part of the criteria for HMS.¹⁸⁻²⁰

The first cases of HMS originated from Cochin, India. Hypotheses for HMS include parental consanguinity and a complex autosomal recessive inheritance.²¹

There have been many reports of PLS from Iran.²²⁻²⁷ Google scholar and pub med searches for the words “Haim-Munk” and “Iran” did not yield any relevant results.

Our patient had typical features of PLS, i.e. being edentulous and having transgradient PPK. Furthermore, he displayed additional features of HMS, i.e. arachnodactyly, onychogryphosis, and flexion contracture of toes and fingers. The psoriasisiform lesions should be differentiated from typical psoriasis, especially in regards to diagnostic and therapeutic approach.²⁸⁻³³

Our patient had two episodes of fever, malaise and sleepiness that healed spontaneously and has had tiredness for the last months. MRI showed multiple bilateral hypersignal T2/FLAIR lesions in periventricular, subcortical, juxtacortical, infratentorial plus multiple patchy hypersignal T2/STIR lesions in C1-2 and C2-4 levels with a final diagnosis of demyelinating

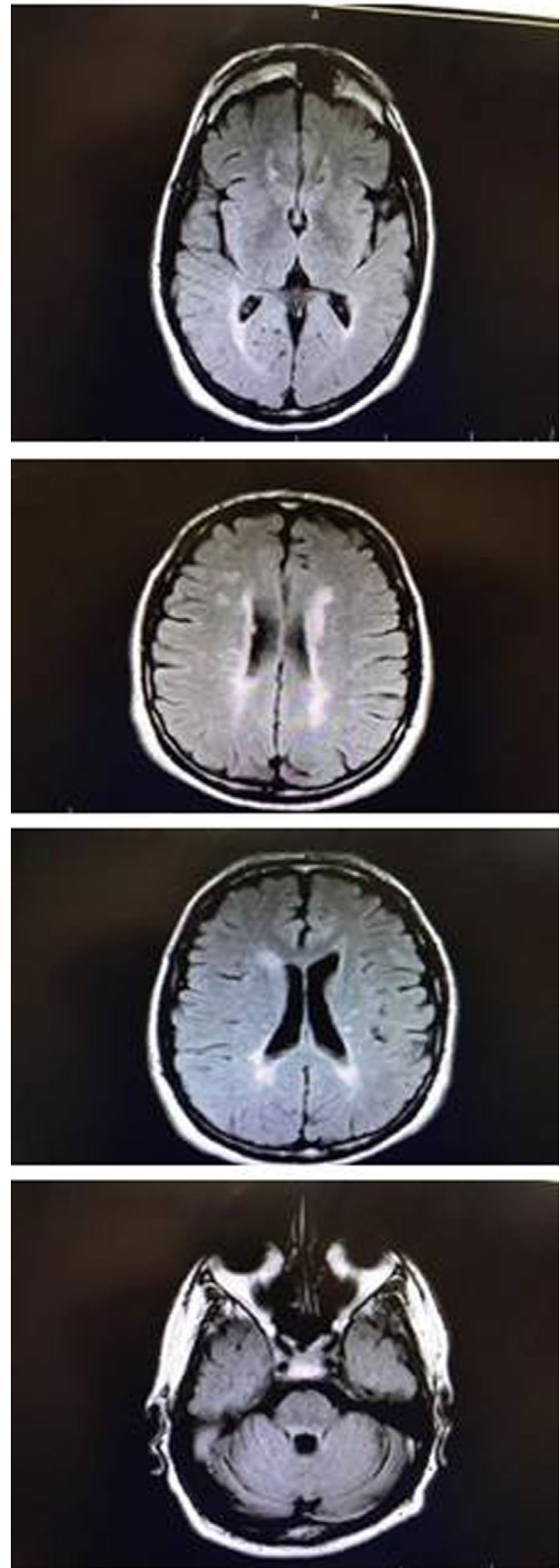


FIGURE 2 Flair T2 sequences of brain shows multiple bright lesions compatible with demyelinating disease (multiple sclerosis)

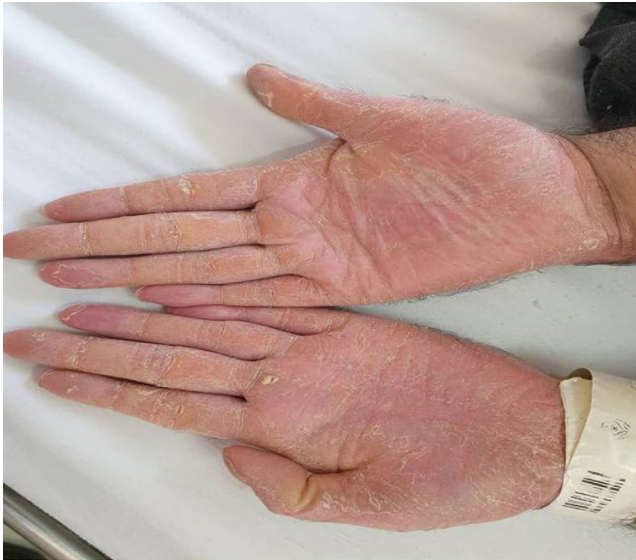

FIGURE 3 Arachnodactyly

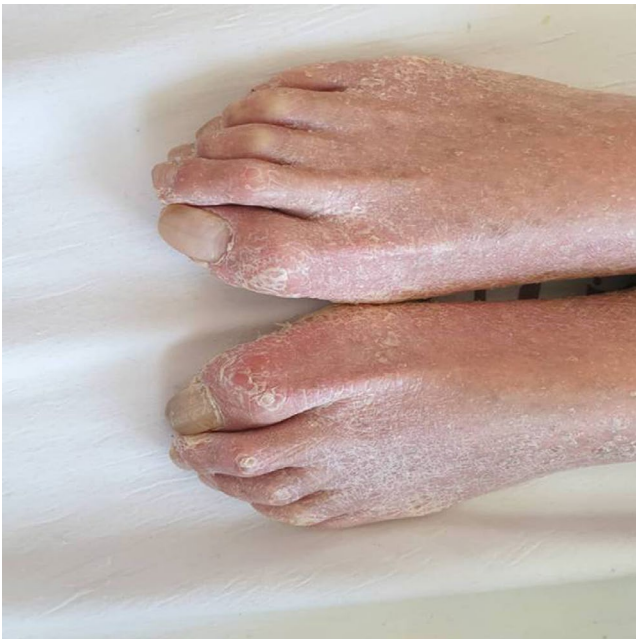

FIGURE 4 Flexion contracture of the toes

disease (Multiple sclerosis). He also suffered from depression and irritability.

Cathepsin C deficiency, which is prevalent in PLS and HMS, has not shown to affect immune dysregulation and autoimmunity. However, other cathepsin deficiencies, such as cathepsin D, is shown to cause neuropathogenesis, such as seizures and demyelination of white matter.⁴

In our opinion, our patient could have mutations in both cathepsin C and other cathepsins, like cathepsin D, or a novel cathepsin C mutation, resulting in neurologic manifestations. This requires further investigations.

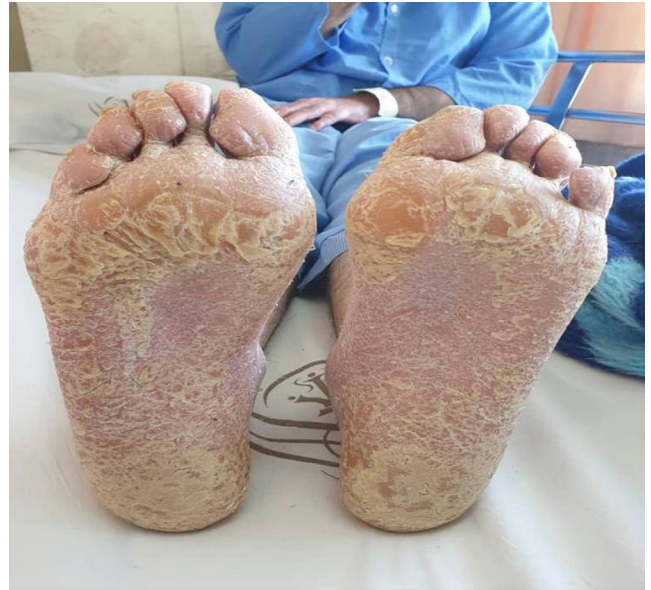

FIGURE 5 Plantar hyperkeratosis

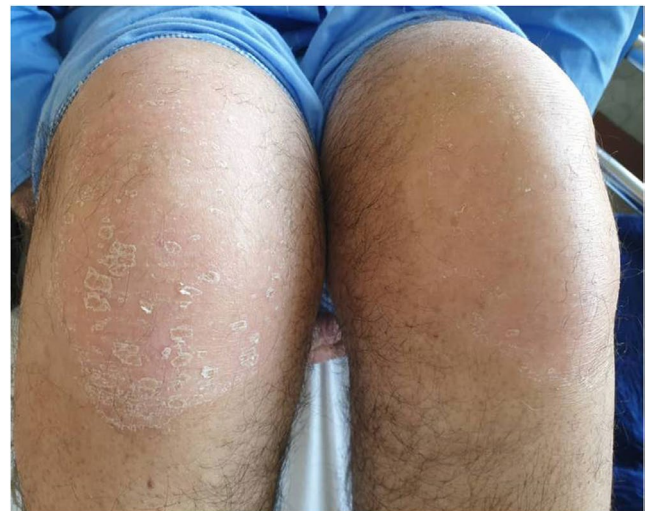

FIGURE 6 Knee hyperkeratosis

Finally, we reviewed and compared latest pubmed publications on PLS and HMS in the past 10 years. We summarized the most important and relevant articles on phenotypic variant, Haim-Munk syndrome, in Table 1.

As is evident from Table 1, there have been reports of psychiatric manifestations like depression and some cases of mental retardation. However, this is a case of PLS/HMS that has MS like signs and symptoms.

4 | CONCLUSION

PLS/HMS can have different psychiatric and neurologic manifestations. They include depression, mental

TABLE 1 Recent reports of PLS/ HMS and their clinical characteristics

source	periodontitis	PPK	Hyperkeratosis	Infection	Other
Adamski Z., et al. 2020 ³⁴	+	+		Purulent URI & Appendicitis	Ear lobe hypoplasia
Alsaif FM, et al. 2019 ³⁵	+	+			Nodular BCC
AbouChedid JC, et al. 2019 ³⁶	+	+	Dorsum of hands & feet		
Yousry YM, et al. 2018 ³⁷	+	+		Pneumonia, Gastroenteritis	
Silva TS, et al. 2018 ³⁸	+	+			
Fageeh HN 2018 ³⁹	+	+	psudoeinhum		Psychotic depression
Lingeswaren A., Gopal SD. 2018 ¹⁵	+	+	Knees (4), Toes (3), dorsal fingers (2)		
AlBarrak Z M., et al. 2016 (5 cases) ⁴⁰	+	+		Pyogenic liver abscess, Gastroenteritis, UTI, Respiratory infection	Pyrexia of unknown origin, Anorexia,
Iqtadar S, et al., 2015 ⁴¹	+	+			Nail dystrophy, transverse nail groove, pointed and clawed fingers in one case
Bhavsar M V., et al., 2013, (2 siblings) ⁴²	+	+	Dorsal of hands & feet, elbows, knees		
Mercy p., et al. 2013 ⁴³	+	+	Elbow, knee	Recurrent skin infections, liver abscess	
Sharma A., et al., 2013 ⁴⁴	+	+	Dorsum of hand joints		
Valeshabad AK., et al. 2012, (6 cases) ²⁵	+	+	Ext. malleolus (5), Knee & elbow (4), dorsal fingers (3), thigh (2)		Depression (6), Mental retardation (4)
Khan FY., et al. 2012, (2 cases) ⁴⁵	+	+	Dorsum of hand and feet and discolored nail in one of them		
Sachdeva S., et al., 2012 ⁴⁶	+	+	Dorsum of hands and feet		
Muppa R., et al. 2011 ⁴⁷	+	+	Dorsum of hands and feet		
Veerabahu BG., et al. 2011 ⁴⁸	+	+	Dorsum of hands and feet, knee, elbow		Malnourish, anemic
Pahwa p., et al. 2010 ¹⁹	+	+	Elbow, lat. Malleolus, Achilles tendon	Recurrent skin infections	Pes planus, nail transversegroove and pitting
Yasar, Halit et al., 2015 ¹⁷	+	+			Nausea, epigastric pain
Kanthimathinathan HK., et al., 2013 ¹⁶	+	+		Brain abscess	

retardation, seizure and abdominal epilepsy. We report PLS/HMS with a demyelinating disorder (MS).

ACKNOWLEDGEMENTS

The authors would like to thank Rasool Akram Medical Complex Clinical Research Development Center (RCRDC) for its technical and editorial assistance.

CONFLICT OF INTEREST

The authors certify that there is no conflict of interest with any financial organization regarding the material discussed in the manuscript.

AUTHOR CONTRIBUTIONS

MM and MG involved in conception and design of the work; MSY, SHH, NM, and AG involved in manuscript preparation and drafting the manuscript; MSY, SHH, NM, and AG involved in searching the literature; All authors involved in critical revision of the manuscript for content. All authors read and approved the final manuscript.

CONSENT

Published with written consent of the patient.

DATA AVAILABILITY STATEMENT

Data are available on reasonable request from the corresponding author.

ORCID

Azadeh Goodarzi  <https://orcid.org/0000-0002-1249-4429>

REFERENCES

- Papillon MM, Lefèvre P. Deuxcas de kératodermie palmatoire et plantairesymetriquefamiliale (maladie de Méléda) chez le frère et la soeur. Coexistence dans les deuxcas d'altérationsdentaires graves. *Bull Soc Fr DermatolSyphiligr*. 1924;31:82-87.
- Gorlin RJ, Sedano H, Anderson VE. The syndrome of palmar-plantar hyperkeratosis and premature periodontal destruction of the teeth. A clinical and genetic analysis of the Papillon-Lefèvre syndrome. *J Pediatr*. 1964;65:895-908.
- Haneke E. The Papillon-Lefèvre syndrome: keratosis palmo-plantaris with periodontopathy. Report of a case and review of the cases in the literature. *Hum Genet*. 1979;51:1-35.
- Ketterer S, Gomez-Auli A, Hillebrand LE, Petretera A, Ketsche A, Reinheckel T. Inherited diseases caused by mutations in cathepsin protease genes. *FEBS J*. 2017;284(10):1437-1454.
- Machado RA, Cuadra-Zelaya FJ M, Martelli-Júnior H, et al. Clinical and molecular analysis in Papillon-Lefèvre syndrome. *Am J Me Genet Part A*. 2019;179(10):2124-2131.
- Haim S, Munk J. Keratosis palmoplantaricongenita, with periodontosis, arachnodactyly and peculiar deformity of the terminal Phalanges. *Bt J Dermatol*. 1965;77:42-54.
- Pap ÉM, Farkas K, Tóth L. Identification of putative genetic modifying factors that influence the development of Papillon-Lefèvre or Haim-Munk syndrome phenotypes. *Clin Exp Dermatol*. 2020;45(5):555-559.
- Guerra L, Castori M, Didona B, Castiglia D, Zambruno G. Hereditary palmoplantar keratodermas. Part II: syndromic palmoplantar keratodermas—Diagnostic algorithm and principles of therapy. *J Eur Acad Dermatol Venereol*. 2018;32(6):899-925.
- Roberts H, White P, Dias I, et al. Characterization of neutrophil function in Papillon-Lefèvre syndrome. *J Leukocyte Biol*. 2016;100(2):433-444.
- Bullón P, Castejón-Vega B, Román-Malo L, et al. Autophagic dysfunction in patients with Papillon-Lefevre syndrome is restored by recombinant cathepsin C treatment. *J Allergy Clin Immunol*. 2018;142(4):1131-1143.
- Zahoor M, Shaikat S, Afza A, Rafat M, Shaikh H, Hussain I. Haim-Munk syndrome with erythroderma-A case report. *J Pakistan Assoc Dermatol*. 2020;30(2):363-366.
- Lidar M, Zlotogorski A, Langevitz P, Tweezer-Zaks N, Zandman-Goddard G. Destructive arthritis in a patient with Haim-munk syndrome. *J Rheumatol*. 2004;31(4):814-817.
- Khan U, Iqar S, Khalid L. Haim munk syndrome: two siblings of southern Pakistan treated with acitretin. *Pakistan Oral Dental J*. 2012;32(1):46-55. http://podj.com.pk/archive/April_2012/12-Podj.pdf
- Tambe LV, Dixit M, Patil N. Papillon lefevre syndrome- A literature review and case report. *IP Internat J Periodontol Implantol*. 2019;4(3):107-112. <https://doi.org/10.18231/j.ijpi.2019.023>
- Lingeswaran A, Gopal SD. A Rare presentation of psychotic depression with suicidality in a case of Papillon-Lefevre syndrome. *Indian J Psychol Med*. 2018;40(4):372-374.
- Kanthimathinathan HK, Browne F, Ramirez R, et al. Multiple cerebral abscesses in Papillon-Lefèvre syndrome. *Child's Nervous System*. 2013;29(8):1227-1229.
- Halit Y, Çayırılı M, Gülses A, et al. Papillon Lefevre syndrome with abdominal epilepsy. *J Turk AcadDermatol*. 2015;9:2.
- Hart TC, Stabholz A, Meyle J, et al. Genetic studies of syndromes with severe periodontitis and palmoplantar hyperkeratosis. *J Periodontol Res*. 1997;32(1):81-89.
- Pahwa P, Lamba AK, Faraz F, Tandon S. Haim-Munk syndrome. *J Indian Soc Periodonto*. 2010;14(3):201.
- Rai R, Thiagarajan S, Mohandas S, Natarajan K, ShanmugaSekar C, Ramalingam S. Haim Munk syndrome and Papillon Lefevre syndrome—allelic mutations in cathepsin C with variation in phenotype. *Int J Dermatol*. 2010;49(5):541-543.
- Hart TC, Hart PS, Michalec MD, et al. Haim-Munk syndrome and Papillon-Lefevre syndrome are allelic mutations in cathepsin C. *J Med Genetics*. 2000;37(2):88-94.
- Ghanei M, Abbaszadegan MR, Forghanifard MM, Aarabi A, Arab H. A novel mutation in the cathepsin C (CTSC) gene in Iranian family with Papillon-Lefevre syndrome. *Clin Exp Dental Res*. 2021:1-6. <https://doi.org/10.1002/cre2.387>
- Moghaddasian M, Arab H, Dadkhah E, Boostani H, Babak AR, Abbaszadegan MR. Protein modeling of cathepsin C mutations found in Papillon-Lefèvre syndrome. *Gene*. 2014;538(1):182-187.
- Farjadian S, Kiyanimanesh N, Abbaszadegan A, Lotfazar M. HLA class I gene polymorphism in Iranian patients with Papillon-Lefevre syndrome. *Iranian J Immunol*. 2007;4(4):241-245.
- KordValeshabad A, Mazidi A, KordValeshabad R, et al. Papillon-Lefevre syndrome: a series of six cases in the same family. *Int Sch Res Notices*. 2012;2012:139104.

26. Farjadian S, Lotfazar M, Ghaderi A. Analysis of human leukocyte antigen class II gene polymorphism in Iranian patients with Papillon-Lefevre syndrome: a family study. *Iranian J Immunol*. 2008;5(3):171-176.
27. Hamissi J, Hamissi H. Papillon-Lefèvre syndrome of Iranian girl: Case report and review of the literature. *Int J Collaborative Res Int Med Public Health*. 2012;4(12):2128.
28. Hallaji Z, Lajevardi V, Abedini R, et al. Serum leptin levels in psoriatic patients with non-alcoholic fatty liver disease. *Iran J Dermatol*. 2016;19:125-130.
29. Abedini R, Goodarzi A, Saeidi V, et al. Serum homocysteine level, vitamin B12 levels, and erythrocyte folate in psoriasis: a case control study. *Int J Womens Dermatol*. 2019;5(3):171-174.
30. Ehsani AH, Mortazavi H, Balighi K, et al. Changes in body mass index and lipid profile in psoriatic patients after treatment with standard protocol of infliximab. *Acta Med Iran*. 2016;54(9):570-575.
31. Lajevardi V, Hallaji Z, Daklan S, Abedini R, Goodarzi A, Abdolreza M. The efficacy of methotrexate plus pioglitazone vs. methotrexate alone in the management of patients with plaque-type psoriasis: a single-blinded randomized controlled trial. *Int J Dermatol*. 2015;54(1):95-101.
32. Vahide L, Maryam G, Pardis H, et al. The effect of narrow band UVB on serum levels of folate: trial on patients with dermatologic disorders. *Iranian J Dermatol*. 2015;18(1):36-37.
33. Feily A, Pazyar N, Khazanee A, Ghassemi MR, Rafiee E. Potential advantages of topical phenytoin as a novel anti psoriasis arsenal. *Nigerian J Med*. 2011;20(2):296.
34. Adamski Z, Burchardt D, Pawlaczyk-Kamieńska T, Borysewicz-Lewicka M, Wyganowska-Świątkowska M. Diagnosis of Papillon-Lefèvre syndrome: review of the literature and a case report. *Adv Dermatol Allergol*. 2020;37(5):671.
35. Alsaif FM, Arafah MA, Alenazi RT, Alotaibi GF. Papillon-Lefèvre syndrome and basal cell carcinoma: a case study. *Case Rep Oncol*. 2019;12(2):411-417.
36. AbouChedid JC, Salameh M, El-Outa A, Noujeim ZEF. Papillon-Lefèvre Syndrome: diagnosis, dental management, and a case report. *Case Rep Dent*. 2019;2019:4210347.
37. Yousry YM, El-Latif AEA, El-Gawad RYA. Case report: clinical manifestation and dental management of Papillon-Lefèvre syndrome. *F1000Res*. 2018;7:1420.
38. Silva TS, Lacerda PN, Rêgo FPA, Rêgo VRPA. Papillon-Lefèvre syndrome. *An Bras Dermatol*. 2018;93(5):771-772.
39. Fageeh HN. Papillon-Lefèvre syndrome: a rare case report of two brothers and review of the literature. *Int J Clin Pediatr Dent*. 2018;11(4):352-355.
40. AlBarrak ZM, Alqarni AS, Chalisserry EP, Anil S. Papillon-Lefèvre syndrome: a series of five cases among siblings. *J Med Case Rep*. 2016;10(1):260.
41. Iqtadar S, Mumtaz SU, Abaidullah S. Papillon-Lefèvre syndrome with palmoplantar keratoderma and periodontitis, a rare cause of pyrexia of unknown origin: a case report. *J Med Case Rep*. 2015;9:288.
42. Bhavsar MV, Brahmabhatt NA, Sahayata VN, Bhavsar NV. Papillon-lefevre syndrome: case series and review of literature. *J Indian SocPeriodontol*. 2013;17(6):806-811.
43. Mercy P, Singh A, Ghorpade AK, Das M, Upadhyay A. Papillon-lefevre syndrome: two siblings, one developing liver abscess. *Indian J Dermatol*. 2013;58(5):410.
44. Sharma A, Kaur G, Sharma A. Papillon-Lefevre syndrome: a case report of 2 affected siblings. *J Indian SocPeriodontol*. 2013;17(3):373-377.
45. Khan FY, Jan SM, Mushtaq M. Papillon-Lefèvre syndrome: case report and review of the literature. *J Indian SocPeriodontol*. 2012;16(2):261-265.
46. Sachdeva S, Kalra N, Kapoor P. Papillon-Lefèvre syndrome: report of a case and its management. *J Clin Exp Dent*. 2012;4(1):e77-e81.
47. Muppa R, Prameela B, Duddu M, Dandempally A. Papillon-lefevre syndrome: a combined approach from the dermatologist and dentist—a clinical presentation. *Indian J Dermatol*. 2011;56(6):740-743.
48. Veerabahu BG, Chandrasekaran S, Alam MN, Krishnan M. Papillon-Lefèvre syndrome. *J Oral MaxillofacPathol*. 2011;15(3):352-357.

How to cite this article: Moghaddasi M, Ghassemi M, Shekari Yazdi M, Habibi SAH, Mohebi N, Goodarzi A. The first case report of Haim Munk disease with neurological manifestations and literature review. *Clin Case Rep*. 2021;9:e04802. <https://doi.org/10.1002/ccr3.4802>