

A Systematic Review of Clinical Studies on Mucocutaneous Manifestations of COVID-19: Virus-Related and Drug-Related

Elham Behrangi, Mohammadreza Ghassemi, Afsaneh Sadeghzadeh-Bazargan, Masoumeh Roohaninasab, Niloufar Najar Nobari, Azadeh Goodarzi

Department of Dermatology, Rasool Akram Medical Complex Clinical Research Development Center (RCRDC), Iran University of Medical Sciences, Tehran, Iran

Received: 12 May 2021; Accepted: 18 Oct. 2021

Abstract- Coronavirus could affect almost any part of the body including the skin. In this systematic review, the primary skin lesions resulting from the direct activity of the virus or the medications used for treatment and the changes in the behavior of the virus regarding the occurrence of these symptoms over time were assessed. PubMed/MEDLINE, Embase, PsycINFO, TRIP Cochrane, Cochrane Skin were searched for all published articles from February 19 to July 1, 2020, which met the inclusion criteria. Thirty-six related articles were extracted. Twenty-eight studies reported virus-related mucocutaneous eruptions and 8 articles, the drug-reactions. Data of 583 patients were included. Skin lesions of COVID-19 could be caused by both the virus itself or the influence of drugs used for the treatment. Morbilliform rashes, urticaria, and acral-vasculopathic cutaneous lesions were at the forefront of primary COVID-dependent skin lesions with no significant change during time. Also, Hydroxychloroquine, lopinavir/ritonavir, paracetamol, and antibiotics were reported as the main causes of drug-induced rashes. Since dermatologic manifestations may occur prior or simultaneously/after other COVID clinical symptoms, so they may helpful in patients' early diagnosis or prediction of internal organ involvements via histopathologic evaluations of skin biopsies especially about vasculopathic and vasculitic, respectively.

© 2021 Tehran University of Medical Sciences. All rights reserved.

Acta Med Iran 2021;59(12):687-698.

Keywords: Coronavirus disease 2019 (COVID-19); Corona; Skin; Cutaneous; Mucocutaneous; Viral rash; Drug rash; Systematic review; Skin rash; Drug eruption; Medicinal rash; Drug; Dermatology; Medication

Introduction

The new Coronavirus disease (COVID-19), first appeared in Wuhan, China and since December 2019, has quickly spread throughout the country (1). The epidemic condition in China is still stable, whereas, the global epidemic of the virus has been widely spread through all countries, particularly in the United States, South Korea, Italy, and Spain (2). Severe acute respiratory syndrome coronavirus 2 (SARS-CoV-2) is a new member of the Coronaviridae family, and its epidemic in Wuhan, China has been transmitted from animal to human. Like other members of the coronavirus family, COVID-19 causes mild to acute respiratory

symptoms (2). Infection caused by this virus could lead to secondary complications in various organs of the body such as heart, liver, and kidney. Furthermore, skin is one of the parts that could be changed in the body of people infected with the coronavirus like other acute respiratory viral diseases (skin rash), however, these changes have not been observed in all patients, and only in some of them up to about 20% have been reported (3). A range of different skin manifestation has been observed during COVID-19 epidemic (4). Some of these skin lesions such as skin eczema are caused by weakness and stress, discontinuation of treatment, delay in treatment, physical and environmental conditions including wearing a mask, latex gloves, washing and

Corresponding Author: A. Goodarzi

Department of Dermatology, Rasool Akram Medical Complex Clinical Research Development Center (RCRDC), Iran University of Medical Sciences, Tehran, Iran

Tel: +98 9123882448, Fax: +98 2142910703, E-mail address: azadeh_goodarzi1984@yahoo.com

Copyright © 2021 Tehran University of Medical Sciences. Published by Tehran University of Medical Sciences

This work is licensed under a Creative Commons Attribution-NonCommercial 4.0 International license (<https://creativecommons.org/licenses/by-nc/4.0/>). Non-commercial uses of the work are permitted, provided the original work is properly cited

disinfecting liquids, and excessive perspiration (5). Some of them, including hives and skin rashes, are often affected by the direct activity of the virus itself (6). In addition, there are dermatoses due to drug reaction associated with COVID-19 treatment, especially skin rashes due to the use of hydroxychloroquine (7,8). Among the 1099 confirmed cases in Wuhan, only 0.2% of patients had skin symptoms (7). The most common cutaneous presentation reported include macular papules, urticaria, COVID fingers (a rash of acral arteries also known as frost-like or pernio-like lesions), finger and acral ischemia, vesicular (chickenpox-like) lesions and levidoreticularis (5). Human skin acts as the body's primary defense mechanism against the external environment. This role is related to the Stratum corneum lipids which maintain the water of the epidermis and prevent foreign objects from entering the inner layers of skin; consequently, it helps immune system to prevent irritation. However, any factor that could damage the structure of the epidermis paves the way for other external objects to enter the skin and stimulates the immune system. Such irritations could be associated with several different types of dermatitis (9). The skin-related side effects of COVID-19 infection are mainly due to the over-influence of hydration (personal protective equipment, PPE), friction, fracture of the epidermal barrier, and contact reactions; All of these may exacerbate a skin condition. Skin manifestations reported due to the impacts of COVID-19 are very different from those recorded in the influenza epidemic during 1918-1919. Erythema, papules, and scaling are the most common skin changes due to prolonged PPE exhaustion (10). According to Adhikari study, during the outbreak of COVID-19 in China, skin symptoms were considered as possible accompanying conditions due to sedatives or occupational skin diseases not related to SARS-CoV-2 (11). In Thailand, samples of petechiae skin rash associated with COVID-19 were reported which were initially confused with dengue. The platelets of these patients were very low (12). Another study stated that rashes on the skin were accidental or true skin rashes caused by COVID-19. However, whether the described lesion is related to the pathophysiological process of COVID-19 must be further investigated (13). There have been several review studies on the skin lesions associated with COVID-19; Given that the disease is a multifaceted disease and its main target is the respiratory system, it often involves other organs as well, and sometimes the patients may have predominant non-respiratory symptoms as well as behavioral changes over time, The present study aimed to investigate the

specific primary skin lesions resulting from the direct activity of the virus or the drugs used for the treatment from all relevant research articles, as well as changes in the virus behavior over the course of these symptoms over time.

Evidence acquisition

The current study is conducted in accordance with PRISMA (Preferred Reporting Items for Systematic Reviews and Meta-Analyze). A comprehensive search is performed in the data bases of PubMed/MEDLINE, Embase, PsycINFO, trip Cochrane, and Cochrane, according to the latest reported cases. In order to collect information in this field, in terms of content, keywords were searched in the desired databases; these keywords included COVID-19, skin, dermatology, cutaneous, urticaria, rash, etc. In the present systematic clinical review, related articles in the forms of case-reports and case-series were included.

Inclusion and exclusion criteria

Inclusion criteria included studies that reported skin manifestations of COVID-19, the treatment of skin disorders and the management of skin patients infected with the coronavirus, and the reaction of anti-corona medications to the skin and skincare during the global pandemic of coronavirus disease. Studies in which there were no reports of skin complications or considerations related to the coronavirus disease, editorial letters, retrospective clinical studies, prospective studies, systematic reviews, and non-English studies were excluded.

Evidence synthesis and Discussion

In this study, a total of 141 articles were reviewed. After removing 35 duplicates, 106 titles and abstracts were assessed for their content validity. After removing 52 articles due to content inconsistency and differences in variables, 64 articles were registered (Figure 1). Finally, after reviewing the type of study and the aim of the study, 36 articles (all articles published from February 19 to July 1, 2020) that met the inclusion criteria and reported the skin side effects of Covid-19 were selected. Amongst these selected articles, there were 31 case report articles, 3 case series articles, 2 perspective articles, and 3 retrospective observational articles. The results of these articles are summarized in Tables 1 and 2.

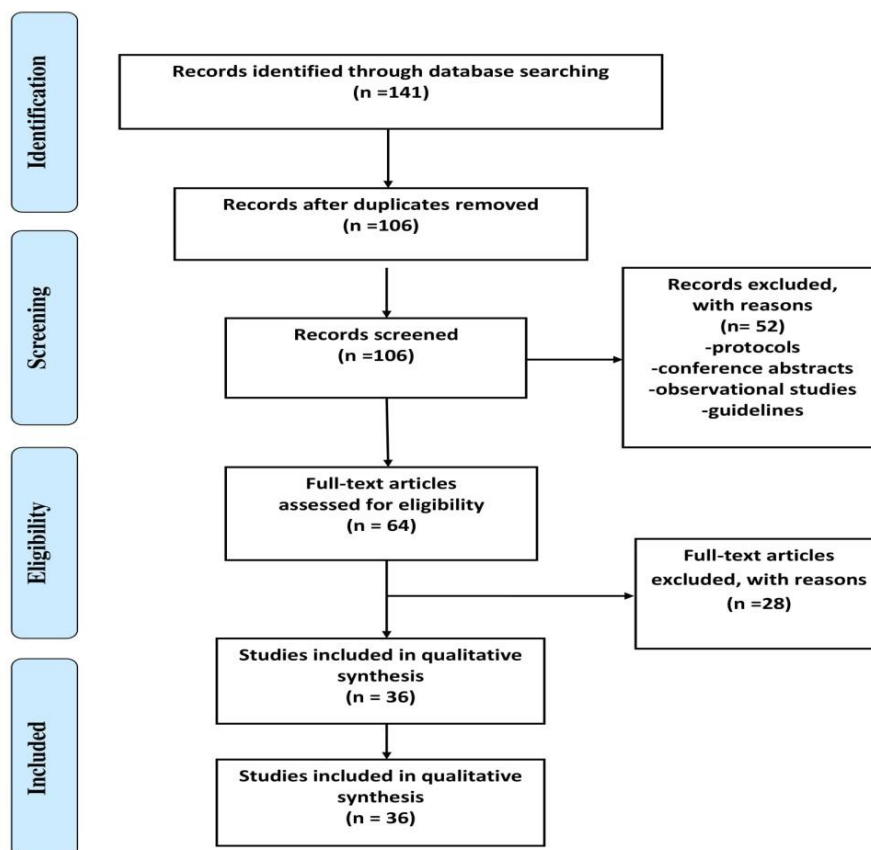


Figure 1. Selection diagram of this systematic review (PRISMA chart)

Table 1. Summary of reviewed articles related to primary viral associated mucocutaneous manifestations of COVID-19

Article Number	1	2	3	4
Topic	COVID-19 could be associated with skin rashes and be confused with dengue fever. (14)	Histological examination of skin lesions in patients with COVID-19 in the northern part of Italy. (15)	The first case of skin manifestations observed in COVID-19 (14)	Response to "COVID-19 could be associated with skin rashes and be confused with dengue fever" Petechiae rash in a patient with COVID-19 (16)
Year/ author	2020 Wiwantkit, Joob	2020 Gianotti, et al	2020 Recalcati	2020 Jimenez, et al
Research type	Case Report	Case Series	Prospective case series	Case Report
Method (number, symptoms location)	In a patient infected with Corona, the symptoms of skin rash were observed along with petechiae.	In 8 patients with Corona disease, widespread spread of maculopapular skin rash and erythematous rash has been observed in parts of the body. Incidence of rash in 2 people from the beginning of the disease and in 6 people after hospitalization.	Of the 88 patients, 18 had erythematous rashes, severe urticarial and chickenpox-like vesicles. Initial incidence in 8 patients and incidence after severity in 10 patients.	In a patient infected with Corona, a maculopapular rash was observed in the flexor and axillary areas.

Systematic review of mucocutaneous signs of COVID

Cont. table 1				
Results	This patient had respiratory problems.	These patients had fever, cough and sore throat.	These patients had fever, fatigue, dry cough, anorexia and shortness of breath.	This patient had acute fever.
Article Number	5	6	7	8
topic	Clinical and coagulation features of 7 patients with acute pneumonia caused by COVID-19 and acro- ischemia (17)	A case with COVID-19 in a young man with spread corporal rashes as an indicator (18)	Incidence of Papulosquamous along with acute respiratory syndrome of Coronavirus (19)	Skin manifestations on COVID-19: skin rashes in a child (20)
Year/ author	2020 Zhang et al	2020 Koziatek & Hunt	2020 Sanchez et al	2020 Olisova et al
Research type	Case Series	Case Report	Case Report	Case Report
Method (number, symptom location)	In 7 patients with Corona, acro- ischemia such as cyanosis of the fingers and toes and blisters of the skin were observed. Six patients were treated with low molecular weight heparin. No report of rash after or before treatment	In a patient with a Corona (a 20-year-old), morbilliform and maculopapular rashes were observed over body and small part of face. Incidence of rashes in patient after infection with disease	An elderly man Incidence periumbilical erythematous rash on the torso, thighs, arms, shoulders and back one day after hospitalization.	A 12-year-old Incidence of purpuric rash and macular erythematous mainly on the upper eyelids, above the eyebrows and temples. Also, her tongue was slightly swollen and irritated by lingual papilla. Incidence of rashes 1 day after fever and evading 3 days after treatment Clinical symptoms including fatigue, pain and fever.
Results	Clinical symptoms included fever, cough, shortness in breath, diarrhea.	This patient had pulmonary infection and fever.	Fever, shortness of breath	
Article Number	9	10	11	12
Topic	Coronavirus in a 15-days infant with clinical symptoms of sepsis (21)	Skin rash of petechial along with acute respiratory syndrome of Coronavirus 2 (22)	Manifestation of dermatology of COVID-19: transient Livedo reticularis (23)	Varicella-like rash as a specific link between COVID disease and skin manifestations: reported cases from several centers in relation with 22 patients (24)
Year/author	2020 Kamali Aghdam et al	2020 Diaz-Guimaraens et al	2020 Manalo	2020 Msrzano et al
Research type	Case Report	Case Report	Case Series	Case Series
Method (number, symptom location)	A 15-day-old infant with Corona disease was observed with skin rashes and hives. Incidence of symptoms at the time of infection to the disease	A 48-year-old man, incidence of erythematous macules on hip, thigh and under belly. Incidence of skin symptoms was observed 3 days after beginning of disease and without taking drug	Two patients Case 1: a 76-year-old man Incidence of unilateral non-itchy livedoid rash on the thigh 7 days after the onset of symptoms and evades within 19 hours Tissue resection was not performed. Case 2: a 47-year-old woman Unilateral; rash on the right foot after sitting in the sun and it goes away in 20 minutes	In 22 patients (with average ages of 60-year-old and 72% men) with Corona, a maculopapular rash similar to varicella was observed in the limbs. time duration average of incidence 8 days (4 to 15 days) Tissue resection was performed in all patients
Results	This infant had fever, lethargy and shortness of breath.	This patient had shortness of breath, fever, chest pain.	Also, this patient had fever and cough.	Clinical symptoms of these patients included fever, headache, cough, fatigue, shortness in breath, diarrhea, muscular pain, runny nose, decreased sense of smell.

Cont. table 1				
Article Number	13	14	15	16
Topic	Two cases of COVID-19 which are shown like cold disease in image. First report from middle east. (25)	Notes and descriptions: skin manifestations in COVID-19: the first view. Safety concerns from clinical images and sampling from skin (26)	Clinical features of 140 patients with SARS-co V-2 in Wuhan, in China (27)	Incidence of hives in patients with COVID-19 (28)
Year/ author	2020 Aldaraji, Alramthan	2020 Fernandez et al	2020 Zhang et al	2020 Henry et al
Research type	Case Series	Case Report	Case Series	Case Report
Method (number, symptom location)	In two patients (two women 27 and 35-year-old) with Corona, acral ischemic lesions appeared as re-people papules on fingers Incidence of skin lesions in the onset of disease and before treatment.	In a patient (32-year-old) with Corona disease, urticarial rashes were observed on the lower torso and thighs The incidence of rashes 6 days after beginning of disease (not because of any drug)	In two patients with Corona disease, hives and rashes were observed on parts of the body. No information was provided about the time of incidence of the rash	In a patient (27-year-old woman) with Corona, the spread of erythematous plaques was observed on the face, hands and feet. The incidence of rashes in the beginning of disease
Results	These two patients referred to doctor due to the skin rashes and without any of common symptoms of Corona, but in the screening test, Corona disease was positive for both.	This patient had the common symptoms of Corona.	This patient had fever, cough, fatigue, chest pain, and gastrointestinal symptoms.	At first, this patient referred to doctor without of any symptoms including fever and cough but after 48 hours had fever, ague, and chest pain.
Article Number	17	18	19	20
Topic	Vascular skin symptoms in COVID-19: an observational study in France (29)	Skin lesions in patient with COVID-19: are these related? (30)	Infant with Corona confirmed with symptoms of eyelid dermatitis (31)	Skin rash as a clinical symptom of patient with COVID-19(32)
Year/ author	2020 Bouaziz et al	2020 Ahouach et al	2020 Wu et al	2020 Pereira & hoeing
research type	Retrospective observational nationwide case series	Case Report	Case Report	Case Report
Method (number, symptoms location)	Incidence of skin symptoms in 14 patients Inflammations of the skin including exanthema in 4 patients, chickenpox vesicles in 2 people, urticarial caused by cold in 1 person Vesicular lesions including purple macules in 1-person, non-necrotic purpura in 1-person, necrotic purpura in 1 person, The incidence of skin symptoms a few days after infection to disease	A patient (57-year-old woman) with Corona With skin rash (erythematous and maculopapular lesions) on the torso and palm of hand Incidence of rashes at the beginning of disease	A 2-year-old and 10-month child Inflammation of the skin of the eye Incidence of complications 7 days after disease and without drug effect	A patient (a 26-year-old man) with Corona, Erythematous, edematous, in case of rash 14 days after the incidence of the disease Treatment of symptoms 20 days of illness
Results	The pathophysiology of these lesions is unclear but may include disorder in immune system adjustment, vasculitis, vascular thrombosis or Neoangiogenesis.	Symptoms of fever, and dry cough.	7 days after infection to Corona skin symptoms were appeared.	Sore through, weakness, pain, cough, anosmia and fever.
Article Number	21	22	23	24
Topic	Infection with SARS-coV-2 APPEARS WITH A RASH DEPENDENT ON FEVER (33)	ACUTE acro-ischemia in children with COVID-19 (34)	Opinion on (cutaneous symptoms in COVID-19; first view (14)	Cold in children in balancing epidemic COVID-19 disease (35)

Cont. table 1

Year/ author	2020 Amatore et al	2020 Mazzotta & Troccoli	2020 Hedou & et al	2020 Andina et al
Research type	Case Report	Case Report	Prospective case series study	A retrospective case series study
Method (number, symptoms location)	A 39-year-old man Incidence of rashes in the form of non-itchy Erythematosis, edematous on chest, neck, belly and palm of hand and face	A 13-year-old boy Incidence of purple Erythematosis on toes	5 cases of 103 patients had skin symptoms. Symptoms of Erythematosis and hives mostly on face and upper part of the body Incidence of rash in 4 persons during disease stages and in 1 person in initial stages Mostly, these rashes were evaded during 48 hours	22 patients (13 boys and 9 girls, with average age of 12 years) Had erythematous-purpuric lesions along with cold symptoms The average of incidence of symptoms were 7 days
Results	This patient had fever and had no signs of involvement of the upper respiratory tract with a lung infection.	At the initial of incidence of rashes, this patient had not any of other symptoms, but after 2 days had fever, body pain, headache, burning sensation in skin lesions.	Itchy	In some of these patients, there are cough, and runny nose.
Article Number	25	26	27	28
Topic	Frostbite is a common skin finding during COVID-19 epidemic: a retrospective study across the France (36)	COVID-19 can be with an itchy popular rash erythematosis: a case study (28)	Frostbite lesions on the foot and hand during COVID-19 epidemic. (37)	Warning for non-respiratory symptoms of patients of coronavirus disease 2919 in the epidemic period; family cluster case report with three asymptomatic COVID-19 patients (38)
Year/ author	2020 De Masson et al	2020 Serafini et al	2020 Landa et al	2020 Lu et al
Research type	A retrospective observational nationwide case series study	Case Report	Case Series	Case Report
Method (number, symptom location)	277 patients (half men and half women with age average of 27 years old) with symptoms of skin rash, petechiae lesion and other skin lesions in most parts of the body. Hives in 26 people (9%), blister in 41 people (51%), acral in 141 people (51%), morbilliform in 25 people (9%), petechial in 7 people (3%) and livedo reticularis in 4 people (1%).	A 32- year- old Incidence of rashes in the form of itchy Erythematosis rash on hand, foot, arm, and back Disappear of rashes 31 days after the appearance	6 patients (with an age average of 35 years old, three men and three women) Had skin lesions like different cold on toe or heel.	In a patient Case 1: the incidence of hives rashes on the skin
Results	These patients had fever, cough, and shortness in breath.	At first patient only had fatigue sensation but 7 days after incidence of rashes had fever, dry cough, and diarrhea.	Mainly, patients had no symptoms of coronavirus and only some of them had cough, fever or congestion	This patient had no other symptoms.

Table 2. Summary of reviewed articles related to drug-associated mucocutaneous manifestations of COVID-19

Article Number	1	2	3	4
Topic	Skin manifestations in COVID-19: report of three cases and review of studies (4)	Skin manifestations in COVID-19: a new achievement (39)	A particular skin rash associated with COVID-19 disease (40)	Completion of vascular damage and microbes associated with thrombosis in the pathogenesis of severe infection: COVID-19 reported from five cases (13)
Year/author	2020 Sachdeva et al	2020 Estebanez et al	2020 Mahe et al	2020 Margo
Research type	Case Series and review study Case 1: a 71-year-old woman diagnosed with COVID-19, maculopapular skin rashes appeared on the torso after the treatment with lopinavir/ritonavir, hydroxychloroquine, rabeprazole, paracetamol, metoclopramide, dihydrocodeine heparin and lactulose. Case 2: a 77 years old woman with maculopapular exanthema (morbilliform) on the torso was accepted and a day after hospitalization macular hemorrhagic was appeared on her foot, the consumed medications included lopinavir/ritonavir and hydroxychloroquine and heparin with low molecular weight. Case 3: after 4 days hospitalization, popular-vesicular rashes and pruritic eruption under chest, torso, and hips of a 72 years old woman were appeared.	Case Report In a patient (a 28-year-old woman) with the Coronavirus disease, erythematous rashes and yellow papules were observed with itching in heel. The incidence of skin rashes 13 days after disease onset and 10 days after taking paracetamol The tissue resection technique was not performed.	Case Report In one patient (a 64-year-old woman with type 2 diabetes) with corona disease, erythematous rashes were observed in the elbow and armpit. The incidence of rashes 4 days after taking paracetamol Vanishing on 9 th day of disease (5 days after appearance).	Case Series Skin lesions were observed in three patients with Corona. Case 1: a 32-year-old, Incidence of network-like purpura rash along with inflammation of the buttocks only 4 day after treatment with hydroxychloroquine, remdesivir and azithromycin. Case 2: a 66-year-old woman, the incidence of dusky purpuric patches on the palm of hand and foot 4 days after taking hydroxychloroquine anticoagulant and prophylactic with enoxaparin Case3: a 40-year-old woman, the incidence of wild skin purpuric after infection to disease
Method (number, symptoms location)				
Results	These patients had fever, cough, headache, swelling of the lymph nodes in the neck and shortness of breath.	This patient had a dry cough, nasal congestion, fatigue, and joint and muscle pain.	This patient had fatigue and high fever.	These three patients referred to doctor due to the Corona and symptoms including myalgia, diarrhea and progressive shortness of breath were observed.
Article Number	5	6	7	8
Topic	Manifestation of skin rashes in children with COVID-19: three cases (41)	Late incidence of widespread skin rash in a patient with a previous COVID-19 infection: viral or multi-drug effect (42)	Exanthem morbilliform related to COVID-19 (43)	The histological pattern in the viral rashes caused by COVID-19 (44)
Year/ author	2020 Duramaz et al	2020 Skroa et al	2020 Najarian	2020 Zengarini et al
Research type	Case Series Three patients Case1: an 8-month-old girl, the incidence of rashes in the form of Rosacea-like erythematous rash (Incidence from the beginning of the disease and their disappearance within two days) Case 2: an 11-year-old girl, rashes were in the form of maculopapular and itch (incidence from the beginning of the disease and their disappearance within 5days) Case 3: a 17-year-old girl, rashes were in the form of maculopapular and itchy (incidence three days after taking HCQ medication) All three patients were on the face and torso	Case Report A 47-year-old hospital employee developed persistent erythematous lesions and itching after taking medications of Ceftriaxone, lopinavir/ritonavir, hydroxychloroquine, enoxaparin Seven days later, all symptoms were evaded.	Case Report A 58-year-old man At first, he had a lot of itching and coughing, and after taking azithromycin were intensified, It had islet-shaped macular erythema on the thigh, feed, forearm, elbow, back, chest, and belly	Case Report A 67-year-old woman Incidence of itchy erythematous rash on the neck, torso, and back one month after taking hydroxychloroquine, omeprazole, piperacillin/ tazobactam/ remdesivir
Method (number, symptom location)				
Results	The lack of relationship between acute rashes and intensity of disease; Existence of normal coagulation patterns in three patients	Neither high fever nor acute respiratory symptoms were observed	This patient had cough and pain on his hand and foot.	This patient had fever and shortness of breath.

In total of 36 studies, mucocutaneous manifestations were observed in 583 patients. The average age of

patients was 40.2 years and among them there were three children (fifteen days old, eight months old, ten months old). The number of affected women with skin rashes was 168 and the number of men was 171. The relationship between Corona disease and dermatologic complications has been mentioned in all articles. Of the total articles, 28 studies reported skin rashes and cutaneous presentation at the onset of the disease or at the time of admission and before the consumption of medication (although some articles did not indicate the time of onset) and in 8 articles, cutaneous presentation and skin lesions were observed after the consumption of medications for the treatment of COVID-19. The highest reported skin lesion in reviewed articles was erythematous rash, which was reported 52.7%, after that maculopapular, acute urticaria, morbilliform rashes, and purpuric eruptions were 22.2%, 22.2%, 11.1%, and 11.1%, respectively. Furthermore, other skin lesions including skin blisters, chickenpox-like vesicles, papulovesicular lesions, edematous lesions, stable macular rash, livedoid lesion and conjunctivitis were reported in the articles. These cutaneous presentation lesions mostly were found on the palms of the hands, feet and their toes (27.7%), on the torso, arms and back (22.2%), lower torso, on the buttocks and thighs (13.8%), and face (11.1%). In addition, the incidence of these rashes all over the body (5.5%), armpit (5.5%), belly and chest (5.5%), foot heel (5.5%) and eyelids, eyebrows and temples (2.7%) were reported. Whereas, according to a review study conducted by Jia *et al.*, in which the published articles between December 31, 2019 to May 3, 2020 were reviewed, highest reported skin lesions for 998 patients from different countries included chickenpox-like lesions (49.2%), hives (22.7%), vesicular lesions (6.4%), necrotic lesions (2.8%), and other types of skin rashes (19.8%) (45).

The most prevalent observed clinical symptoms in these patients included fever (63.8% of articles), cough (46.4%), shortness of breath, and respiratory problems (in 30.5% of cases), fatigue (22.2%), and diarrhea (11.14%). Other symptoms such as chest pain, hand and foot pain, sore throat, anorexia, decreased sense of smell and gastrointestinal symptoms were also observed among patients. However, not all studies reported the mean duration of onset or disappearance of these skin manifestations, but in total, symptoms appear in patients within nine days, on average, and after 6 to 9 days since the incidence of Corona symptoms, these lesions have disappeared, however, in two articles, the time reported was less than one day (19 hours and 20 minutes). Improvement of skin symptoms has been reported between 2 and 15 days after the improvement of

coronavirus disease (14). According to the extracted data from Table 2, the medications that caused skin complications in patients with COVID-19 included Hydroxychloroquine (87.5%, 6 of 8 articles), lopinavir/ritonavir (37.5%), paracetamol (37.5%), heparin (25%), azithromycin (25%), remdesivir (25%), enoxaparin (25%), rabeprazole (12.5%), metoclopramide (12.5%), dihydrocodeine (12.5%), lactulose (12.5%), ceftriaxone (12.5%), omeprazole (12.5%), piperacillin/tazobactam (12.5). Reported skin complications in this group of articles included erythematous rash, maculopapular, purpuric rash, and morbilliform. The average duration of these symptoms after consumption of the drug was 7 to 8 days. The shortest duration of incidence was 3 days and the longest duration was 30 days after the consumption of medication.

In the current study, articles published from February 19 to July 1, in 2020 were investigated. The reported skin lesions in articles published in February, were hives and erythematous rashes; in articles published in March, erythematous rash, hives, chicken pox-like vesicles, blister, morbilliform rash and maculopapular eruptions were reported. COVID-related skin lesions reported in April included erythematous rashes, maculopapular, hives, chickenpox-like vesicles, edematous lesions, Frostbite-like lesions and conjunctivitis. In articles published in May, complications of urticarial, erythematous rash, maculopapular, livedoid and blister, and in June, urticarial, purpuric rash, and in July, erythematous lesions and urticarial were reported. In reviewing these articles, it appears that the behavior of the virus has not changed during the months under review, and the lesions reported in different months are almost identical.

Skin manifestations are important in the diagnosis of different infectious diseases including toxic shock, meningococemia, rickettsial diseases, measles and scarlet fever (4). Also, there are various types of cutaneous manifestations among the skin lesions caused by viruses. In most cases, this is only an exanthem or skin diseases which indicates the outbreak of the virus through the cutaneous vascular system, in which in later stages they could activate the immune system by mobilizing lymphocytes and Langerhans cells that pass through the skin's lymph nodes. Following that they could activate T and CD4 lymphocytes to produce cytokines such as IL-1, IFN- γ , and TNF- α and then implement eosinophils, cytotoxicity T cells, CD8, B cells, natural killer cells (NK), which leads to lymphocytic thrombophilic arteritis. Then, acute viral infection could activate the cytokine

cascade, which stimulates the CID phenomenon; This may occur in the skin, lungs, and kidneys of all patients (4,15). On the other hand, manifestations similar to levidoreticularis can be the result of accumulation of microtubules originating from other organs; consequently, blood flow to the dermal microvascular system is reduced (4). Since the COVID-19 is asymptomatic for up to 14 days after the infection, skin manifestations may be a symptom of the diseases and could aid in early diagnosis (4). In this disease, the clinical image is very similar to the exanthema around a cavity caused by parvovirus B19. Skin biopsy specimens from patients with the disease show a mononuclear perivascular inflammation and extravasated eosinophils and erythrocytes. In addition, viral proteins of parvovirus B19 are found in endothelial cells of cutaneous vessels and may be involved in the pathogenesis of purpura (46). It is hypothesized that COVID-19 could similarly affect the skin. In this case, histopathologic features of COVID-19 (for instance, parakeratotic areas, mild spongiosis and extravasated red blood cells) may overlap with pityriasis rosea histopathologic features, which seems to have viral pathogenicity (47).

Some studies suggest that the skin side effects of COVID-19 infection are mainly due to the effects of excessive hydration, epidermal barrier failure, and contact reactions, all of which may exacerbate a skin condition. Skin complications of the coronavirus disease are different from influenza (10) Joob *et al.*, (2020) expressed that skin rashes were accidental or real skin rashes caused by COVID-19 (16). Marzano *et al.*, (2020) reported that the characteristic features of this skin rash are torso involvement, scattered distribution, and mild itching, and the lesions generally appear 3 days after the onset of systemic symptoms and disappear without scarring after 8 days (24).

In some cases, it has been reported that undesirable drug reactions and interactions in treatment, cause secondary skin reactions at every stage of the disease (11,48). In review research conducted by Suchonwanit *et al.*, the undesirable effects of drugs on patients were presented. According to this study, medications such as hydroxychloroquine, azithromycin, lopinavir/ritonavir, corticosteroids, and tocilizumab had caused complications, including pruritus, hair loss, morbilliform rash, and red spots (48). These effects were also observed in some of the articles reviewed in the current study. Viral rashes and drug-induced reactions are clinically and histologically similar and are often difficult to distinguish. In order to assess the cause, a complete history of the patient should be obtained, especially the possible drugs

that were chosen for the treatment, and the relationship between the timing of drug consumption and the onset of COVID-19 symptoms (16). On the contrary, whether the skin lesions in patients with COVID-19 are associated with the virus or not, is an issue which is still unknown. Dermatologists must consider that skin rashes in patients with COVID-19 may be due to viral infections, systemic consequences, or prescribed medications. Early recognition of skin symptoms, which is associated with severe complications and rapid management, is essential for the treatment of patients. Additionally, to understand the precise skin features as a means for a more accurate diagnosis that may predict the disease outcomes in particular patients, more clinical studies on the skin manifestations of COVID-19 are needed (48). The authors of this article have been worked on various aspects of dermatologic issues in the setting of COVID-19 including mucocutaneous presentation and therapeutic consideration (8,49-51), approaches to patients with specific skin disorders or any comorbidities affected by virus (5,52) and potential multi-functional drugs for therapy, (53,54) we are really tried to summarized available related data in a well-structured manner in this systematic review. This systematic review is among the hot topic conducted on covid-19- related dermatological disorders. Moreover, the authors have many studies on covid-19 that may be helpful for other researchers in this field (55-64).

In this current systematic review, clinical symptoms of 583 patients were reviewed and the results demonstrated that the skin was commonly affected by the coronavirus infection. The results also illustrated that the incidence of skin lesions of this disease could occur both under the influence of the virus and under the influence of consumed medications for the treatment of this disease. According to the results of this study, Hydroxychloroquine, lopinavir/ritonavir, paracetamol, and antibiotics were reported as the main causes of drug-induced rashes in the treatment of the disease. Also, the review of published articles demonstrated that the behavior of the virus in the development of skin rashes and cutaneous presentation had not changed significantly over time, and the lesions were almost identical and repetitive; thus, morbilliform rashes, urticaria, and acral-vasculopathy cutaneous lesions were at the forefront of primary COVID-dependent skin lesions. Further studies are required on the cause of skin complications and a better understanding of the underlying pathogenesis. Since the COVID-19 is asymptomatic for up to 14 days after the infection, skin manifestations may be a symptom of the disease and could aid in early diagnosis. When the

skin lesions occur simultaneously or after the onset of the main clinical symptoms of COVID, a skin biopsy would be a valuable tool in investigating possible histopathological events associated with the disease in the internal organs because the skin, especially vasculopathy and vasculitic skin lesions (retiform purpura, chilblain-like lesions, pernio-like, COVID Toe, petechiae, purpura, etc.), could be a mirror for the pathological events in the body. The recognition of skin manifestations of COVID-19 including the primary skin complications associated with the disease or the treatment, the most common clinical presentations, the most common medications that cause skin lesions to appear before or after the other clinical symptoms, evaluation of changes in presentations over time (due to changes in the non-cutaneous clinical presentations of COVID-19 in different communities and overtime and the multiplicity of the disease in general), and determining the relationship between skin presentation type and latent and main clinical consequences of COVID are the most important goals of dermatological studies in the COVID-19 pandemic. On the other hand, the management of patients with known dermatoses, who are being treated, is highly important, both in terms of how to continue treatment in the pandemic and in terms of approaches in case of infection.

Acknowledgments

The authors would like to thank the Rasool Akram Medical Complex Clinical Research Development Centre (RCRDC) for its technical and editorial assist.

References

1. Guan WJ, Ni ZY, Hu Y, Liang WH, Ou CG, He JX, et al. Clinical characteristics of coronavirus disease 2019 in China. *New Engl J Med* 2020;382:1708-20.
2. Kurdoğlu M, Khaki A. What Is the Current State of Knowledge About the Novel Coronavirus Infection During Pregnancy? *Int J Womens Health Reprod Sci* 2020;8:110-11.
3. Yan Y, Chen H, Chen L, Cheng B, Diao P, Dong L, et al. Consensus of Chinese experts on protection of skin and mucous membrane barrier for health-care workers fighting against coronavirus disease 2019. *Dermatol Ther* 2020;33:e13310.
4. Sachdeva M, Gianotti R, Shah M, Lucia B, Tosi D, Veraldi S, et al. Cutaneous manifestations of COVID-19: Report of three cases and a review of literature. *J Dermatol Sci* 2020;98:75-81.
5. Najar Nobari N, Goodarzi A. Patients with specific skin disorders who are affected by COVID-19: what do experiences say about management strategies? A systematic review. *Dermatol Ther* 2020;33:e13867.
6. Vaira LA, Salzano G, Deiana G, De Riu G. In Response to Anosmia and Ageusia: Common Findings in COVID-19 Patients. *Laryngoscope* 2020;130:1787.
7. Wollina U, Karadağ AS, Rowland-Payne C, Chiriac A, Lotti T. Cutaneous Signs in COVID-19 Patients: A Review. *Dermatol Therapy* 2020;33:e13549.
8. Seirafianpour F, Sodagar S, Mohammad AP, Panahi P, Mozafarpour S, Almasi S, et al. Cutaneous manifestations and considerations in COVID-19 pandemic: A systematic review. *Dermatol Ther* 2020;33:e13986.
9. van Smeden J, Bouwstra JA. Stratum corneum lipids: their role for the skin barrier function in healthy subjects and atopic dermatitis patients. *Curr Probl Dermatol* 2016;49:8-26.
10. Wang JV, Parish LC. Dermatologic Manifestations of the 1918-1919 Influenza Pandemic. *Skinmed* 2019;17:296-7.
11. Adhikari SP, Meng S, Wu YJ, Mao YP, Ye RX, Wang QZ, et al. Epidemiology, causes, clinical manifestation and diagnosis, prevention and control of coronavirus disease (COVID-19) during the early outbreak period: a scoping review. *Infect Dis Poverty* 2020;9:29.
12. Joob B, Wiwanitkit V. COVID-19 in medical personnel: observation from Thailand. *J Hosp Infect* 2020;104:453.
13. Magro C, Mulvey JJ, Berlin D, Nuovo G, Salvatore S, Harp J, et al. Complement associated microvascular injury and thrombosis in the pathogenesis of severe COVID-19 infection: a report of five cases. *Transl Res* 2020;220:1-13.
14. Recalcati S. Cutaneous manifestations in COVID-19: a first perspective. *J Eur Acad Dermatol Venereol* 2020;34:e212-3.
15. Gianotti R, Zerbi P, Dodiuk-Gad RP. Clinical and histopathological study of skin dermatoses in patients affected by COVID-19 infection in the Northern part of Italy. *J Dermatol Sci* 2020;98:141-3.
16. Joob B, Wiwanitkit V. COVID-19 can present with a rash and be mistaken for Dengue. *J Am Acad Dermatol* 2020;82:e177.
17. Xiao Y, Liu Y, Zheng S, Yang Y, Fan S, Yang C, et al. Relationship between hypertension and body mass index, waist circumference and waist-hip ratio in middle-aged and elderly residents. *Zhonghua liu xing bing xue za zhi* 2016;37:1223-7.
18. Hunt M, Koziatek C. A Case of COVID-19 Pneumonia in a Young Male with Full Body Rash as a Presenting. *Clin Pract Cases Emerg Med* 2020;4:219-21.
19. Sanchez A, Sohler P, Benghanem S, L'Honneur AS,

- Rozenberg F, Dupin N, et al. Digitate papulosquamous eruption associated with severe acute respiratory syndrome coronavirus 2 infection. *JAMA Dermatol* 2020;156:819-20.
20. Olisova OY, Anpilogova E, Shnakhova L. Cutaneous manifestations in COVID-19: a skin rash in a child. *Dermatol Ther* 2020;33:e13712.
 21. Kamali Aghdam M, Jafari N, Eftekhari K. Novel coronavirus in a 15-day-old neonate with clinical signs of sepsis, a case report. *Infect Dis (Lond)*2020;52:427-9.
 22. Diaz-Guimaraens B, Dominguez-Santas M, Suarez-Valle A, Pindado-Ortega C, Selda-Enriquez G, Bea-Ardebol S, et al. Petechial skin rash associated with severe acute respiratory syndrome coronavirus 2 infection. *JAMA Dermatol* 2020;156:820-2.
 23. Manalo IF, Smith MK, Cheeley J, Jacobs R. A dermatologic manifestation of COVID-19: transient livedo reticularis. *J Am Acad Dermatol* 2020;83:700.
 24. Marzano AV, Genovese G, Fabbrocini G, Pigatto P, Monfrecola G, Piraccini BM, et al. Varicella-like exanthem as a specific COVID-19-associated skin manifestation: Multicenter case series of 22 patients. *J Am Acad Dermatol* 2020;83:280-5.
 25. Alramthan A, Aldaraji W. Two cases of COVID-19 presenting with a clinical picture resembling chilblains: first report from the Middle East. *Clin Exp Dermatol* 2020;45:746-8.
 26. Fernandez-Nieto D, Ortega-Quijano D, Segurado-Miravalles G, Pindado-Ortega C, Prieto-Barrios M, Jimenez-Cauhe J. Comment on: Cutaneous manifestations in COVID-19: a first perspective. Safety concerns of clinical images and skin biopsies. *J Eur Acad Dermatol Venereol* 2020;34:e252-e4.
 27. Zhang JJ, Dong X, Yd Y, Yq Y. Clinical characteristics of 140 patients infected with SARS-CoV-2 in Wuhan. China n/a (n/a). *Allergy* 2020;75:1730-41.
 28. Henry D, Ackerman M, Sancelme E, Finon A, Esteve E. Urticarial eruption in COVID-19 infection. *J Eur Acad Dermat Venereol* 2020;34:e244-e5.
 29. Bouaziz J, Duong T, Jachiet M, Velter C, Lestang P, Cassius C, et al. Vascular skin symptoms in COVID-19: a french observational study. *J Eur Acad Dermatol Venereol* 2020;34:e451-2.
 30. Ahouach B, Harant S, Ullmer A, Martres P, Bégon E, Blum L, et al. Cutaneous lesions in a patient with COVID-19: are they related? *Br J Dermatol* 2020;183:e31.
 31. Wu P, Liang L, Chen C, Nie S. A child confirmed COVID-19 with only symptoms of conjunctivitis and eyelid dermatitis. *Graefes Arch Clin Exp Ophthalmol* 2020;258:1565-6.
 32. Hoenig LJ, Pereira FA. Eruption as a clinical manifestation of COVID-19: Photographs of a patient. *Clin Dermatol* 2020;38:502-5.
 33. Amatore F, Macagno N, Mailhe M, Demarez B, Gaudy-Marqueste C, Grob J, et al. SARS-CoV-2 infection presenting as a febrile rash. *J Eur Acad Dermatol Venereol* 2020;34:e304-e306.
 34. Mazzotta F, Troccoli T. Acute acro-ischemia in the child at the time of COVID-19. *Eur J Pediatr Dermatol* 2020;30:71-4.
 35. Andina D, Noguera-Morel L, Bascuas-Arribas M, Gaitero-Tristán J, Alonso-Cadenas JA, Escalada-Pellitero S, et al. Chilblains in children in the setting of COVID-19 pandemic. *Pediatr Dermatol* 2020;37:406-11.
 36. de Masson A, Bouaziz JD, Sulimovic L, Cassius C, Jachiet M, Ionescu M-A, et al. Chilblains are a common cutaneous finding during the COVID-19 pandemic: a retrospective nationwide study from France. *J Am Acad Dermatol* 2020;83:667-70.
 37. Landa N, Mendieta-Eckert M, Fonda-Pascual P, Aguirre T. Chilblain-like lesions on feet and hands during the COVID-19 Pandemic. *Int J Dermatol* 2020;59:739-43.
 38. Lu S, Lin J, Zhang Z, Xiao L, Jiang Z, Chen J, et al. Alert for non-respiratory symptoms of Coronavirus Disease 2019 (COVID-19) patients in epidemic period: a case report of familial cluster with three asymptomatic COVID-19 patients. *J Med Virol* 2021;93:518-21.
 39. Estébanez A, Pérez-Santiago L, Silva E, Guillen-Climent S, García-Vázquez A, Ramón MD. Cutaneous manifestations in COVID-19: a new contribution. *J Eur Acad Dermatol Venereol* 2020;34:e250-1.
 40. Mahé A, Birckel E, Krieger S, Merklen C, Bottlaender L. A distinctive skin rash associated with Coronavirus Disease 2019? *J Eur Acad Dermatol Venereol* 2020;34:e246-7.
 41. Duramaz BB, Yozgat CY, Yozgat Y, Turel O. Appearance of skin rash in pediatric patients with COVID-19: Three case presentations. *Dermatol Ther* 2020;33:e13594.
 42. Skroza N, Bernardini N, Balduzzi V, Mambrin A, Marchesiello A, Michelini S, et al. A late onset widespread skin rash in a previous Covid-19 infected patient: viral or multidrug effect? *J Eur Acad Dermatol Venereol* 2020 Sep;34:e438-9.
 43. Najarian DJ. Morbilliform exanthem associated with COVID-19. *JAAD Case Rep* 2020;6:493-4.
 44. Zengarini C, Orioni G, Cascavilla A, Horna Solera C, Fulgaro C, Misciali C, et al. Histological pattern in Covid-19 induced viral rash. *J Eur Acad Dermatol Venereol* 2020;34:e453-4
 45. Jia JL, Kamceva M, Rao SA, Linos E. Cutaneous

Systematic review of mucocutaneous signs of COVID

- manifestations of COVID-19: a preliminary review. *J Am Acad Dermatol* 2020;83:687-90.
46. Santonja C, Pielasinski Ú, Polo J, Kutzner H, Requena L. Immunohistochemical Demonstration of Parvovirus B19 Viral Protein 2 in Periflexural Exanthema in an Adult, Supporting Antibody-Dependent Enhancement as Means of Endothelial Uptake of the Virus. *Am J Dermatopathol* 2018;40:e19-24.
 47. Prantsidis A, Rigopoulos D, Papatheodorou G, Menounos P, Gregoriou S, Alexiou-Mousatou I, et al. Detection of human herpesvirus 8 in the skin of patients with pityriasis rosea. *Acta Derm Venereol* 2009;89:604-6.
 48. Suchonwanit P, Leerunyakul K, Kositkuljorn C. Cutaneous manifestations in COVID-19: Lessons learned from current evidence. *J Am Acad Dermatol* 2020;83:e57-60.
 49. Sadeghzadeh Bazargan A, Behrangi E, Goodarzi A. Cytokine storm and probable role of immunoregulatory drugs in COVID-19: A comprehensive review study. *Iran J Dermatol* 2020;23:S13-8.
 50. Sadeghzadeh Bazargan A, Behrangi E, Goodarzi A. Systemic retinoids in the COVID-19 era – are they helpful, safe, or harmful? a comprehensive systematized review study. *Iran J Dermatol* 2020;23:S9-12.
 51. Atefi NS, Behrangi E, Mozafarpour S, Seirafianpour F, Peighambari S, Goodarzi A. N acetylcysteine and coronavirus disease 2019: May it work as a beneficial preventive and adjuvant therapy? A comprehensive review study. *J Res Med Sci* 2020;25:109.
 52. Mohamadi MM, Goodarzi A, Aryannejad A, Fattahi N, Alizadeh-Khoei M, Miri S, et al. Geriatric challenges in the new coronavirus disease-19 (COVID-19) pandemic: A systematic review. *Med J Islam Repub Iran* 2020;34:123.
 53. Seirafianpour F, Mozafarpour S, Fattahi N, Sadeghzadeh-Bazargan A, Hanifiha M, Goodarzi A. Treatment of COVID-19 with pentoxifylline: Could it be a potential adjuvant therapy? *Dermatol Ther* 2020;33:e13733.
 54. Najar Nobari N, Seirafianpour F, Mashayekhi F, Goodarzi A. A systematic review on treatment-related mucocutaneous reactions in COVID-19 patients. *Dermatol Ther* 2021;34:e14662.
 55. Mohamadi M, Fattahi N, Goodarzi A, Alizadeh-Khoei M, Miri Sh, Hekmat H, et al. A Comprehensive Review on COVID-19 Infection and Comorbidities of Various Organs. *Acta Med Iran* 2021;59:4-14.
 56. Najar Nobari N, Montazer F, Seirafianpour F, Nikkhah F, Aryanian Z, Goodarzi, A. Histopathologic Changes and Cellular Events of Organs Systems in COVID-19. *J Cell Mol Anesth* 2021;6:81-8.
 57. Kooranifar S, Sadeghipour A, Riahi T, Goodarzi A, Tabrizi S, Davoody N. Histopathologic survey on lung necropsy specimens of 15 patients who died from COVID-19: A large study from Iran with a high rate of anthracosis. *Med J Islam Repub Iran* 2021;35:63.
 58. Najar Nobari N, Seirafianpour F, Dodangeh M, Sadeghzadeh-Bazargan A, Behrangi E, Mozafarpour S, et al. A systematic review of the histopathologic survey on skin biopsies in patients with Corona Virus Disease 2019 (COVID-19) who developed virus or drug-related mucocutaneous manifestations. *Exp Dermatol* 2021;30:1233-53.
 59. Sadeghzadeh-Bazargan A, Rezaei M, Najar Nobari N, Mozafarpour S, Goodarzi A. Skin manifestations as potential symptoms of diffuse vascular injury in critical COVID-19 patients. *J Cutan Pathol* 2021;48:1266-76.
 60. Kalantari S, Sadeghzadeh-Bazargan A, Ebrahimi S, Yassin Z, Faiz SHR, Kabir A, et al. The effect of influenza vaccine on severity of COVID-19 infection: An original study from Iran. *Med J Islam Repub Iran* 2021;35:114.
 61. Riahi T, Sadeghzadeh-Bazargan A, Shokri S, Ahmadvand D, Hassanlouei B, Baghestani A, et al. The effect of opium on severity of COVID-19 infection: An original study from Iran. *Med J Islam Repub Iran* 2021;35:115.
 62. Tavakolpour S, Aryanian Z, Seirafianpour F, Dodangeh M, Etesami I, Daneshpazhooch M, et al. A systematic review on efficacy, safety, and treatment-durability of low-dose rituximab for the treatment of Pemphigus: special focus on COVID-19 pandemic concerns. *Immunopharmacol Immunotoxicol* 2021;43:507-18.
 63. Mashayekhi F, Seirafianpour F, Pour Mohammad A, Goodarzi A. Severe and life-threatening COVID-19-related mucocutaneous eruptions: A systematic review. *Int J Clin Pract* 2021;e14720.
 64. Lotfi Z, Haghghi A, Akbarzadehpasha A, Mozafarpour S, Goodarzi A. Pansclerotic morphea following COVID-19: A case report and review of literature on rheumatologic and non-rheumatologic dermatologic immune-mediated disorders induced by SARS-CoV-2. *Front Med* 2021;8:728411.