

Treatment of tongue lymphangioma circumscriptum with non-ablative long-pulsed Nd:YAG laser: a case report and review of literature

Samaneh Mozafarpour, MD ^{1†*}
 Ali Asilian, MD ¹
 Azadeh Goodarzi, MD ^{2†}
 Zahra Ebrahimi, MD ³
 Fatemeh Mokhtari, MD ^{1,4}
 Zeynab Rastgar Moqaddam ³

1. Department of Dermatology, Skin Diseases and Leishmaniasis Research Center, Isfahan University of Medical Sciences, Isfahan, Iran
2. Department of Dermatology, Rasool Akram Medical Complex, Iran University of Medical Sciences, Tehran, Iran
3. Department of General Medicine, Iran University of Medical Sciences, Tehran, Iran
4. Department of Dermatology, Al-Zahra Hospital, Isfahan University of Medical Sciences, Isfahan, Iran

† These authors equally contributed preparing this article and are co-first authors

*Corresponding author:
 Samaneh Mozafarpour, MD
 Department of Dermatology, Skin Diseases and Leishmaniasis Research Center, Isfahan University of Medical Sciences, Isfahan, Iran
 Email: Samane.mp82@yahoo.com

Received: 27 June 2021
 Accepted: 13 July 2021

INTRODUCTION

Lymphangioma is an unusual congenital malformation of the lymphatic system that affects the skin and subcutaneous tissues ¹. About 50% of lymphangioma lesions are present at birth, and 80% may be noted before the second year of life ². Oral lymphangiomas often occur in the anterior

Lymphangioma is an unusual congenital malformation of the lymphatic system that affects the skin and subcutaneous tissue. A surgical procedure is among the options for lymphangioma treatment, although it can lead to significant complications. The Nd:YAG Laser appears to be one of the safest therapeutic options rarely proposed to treat oral cavity lesions. This paper comprehensively reviewed the studies published from 2010 to date on the treatment of cutaneous and mucosal lymphangioma with different types of lasers. In the current report, an 18-year-old female presented with a lymphangiomatous lesion on the tongue diagnosed through a pathologic study. The patient initially underwent three sessions of pulsed-dye laser (PDL) therapy that evoked an insignificant response. Therefore, the approach was changed to long-pulsed Nd:YAG laser therapy, and a dramatic response was observed within three sessions of the treatment.

Keywords: lymphangioma, lymphangioma circumscriptum, tongue, mucosal, laser, Nd:YAG laser, long-pulsed Nd YAG laser, treatment, therapy, CO2 laser, review

Iran J Dermatol 2021; 24: 242-248

DOI: 10.22034/ijid.2021.292129.1395

two-thirds of the tongue but can also affect the oral mucosa, gums, palate, and lips ^{3,4}. Surgical treatment is the definitive treatment choice for this lesion. However, depending on the lesion position, size, and probability of bleeding, it might not be simple or lead to the desired results and can entail surgical complications ⁵.

This study portrays the case of an eighteen-year-

old woman with congenital tongue lymphangioma treated via PDL (two sessions) without satisfactory results. The case was then successfully treated with three sessions of long-pulsed Nd:YAG laser therapy. Furthermore, we present a review of studies from 2010 to date on the treatment of cutaneous and mucosal lymphangiomas with different types of lasers.

CASE PRESENTATION

An 18-year-old woman presented to a physician with complaints of a burning tongue sensation and inability to chew. Physical examination revealed a hyperplastic lesion (1×2 cm²) on the dorsal part of her tongue. She had had this lesion since her first

year of life (Figure 1) but received no medication since the time of referral. The affected area was thoroughly examined, and the required biopsies were obtained. Pathologic studies showed large lymphatic areas covered by endothelial epithelium and plump cells in the dermal region. Nothing was found in favor of malignancy, indicating the diagnosis of lymphangioma (Figure 2).

The pulsed-dye laser (PDL) (DEKA Company, Italy, 2016) was initially administered to treat the lesion. The first laser therapy session was performed with a fluency of 6 J/cm², a pulse width of 3 ms, and shot numbers of 31, followed by another session using the vascular mode with a fluency of 6.5 J/cm² and shots of 30. The patient displayed nonsignificant improvement following

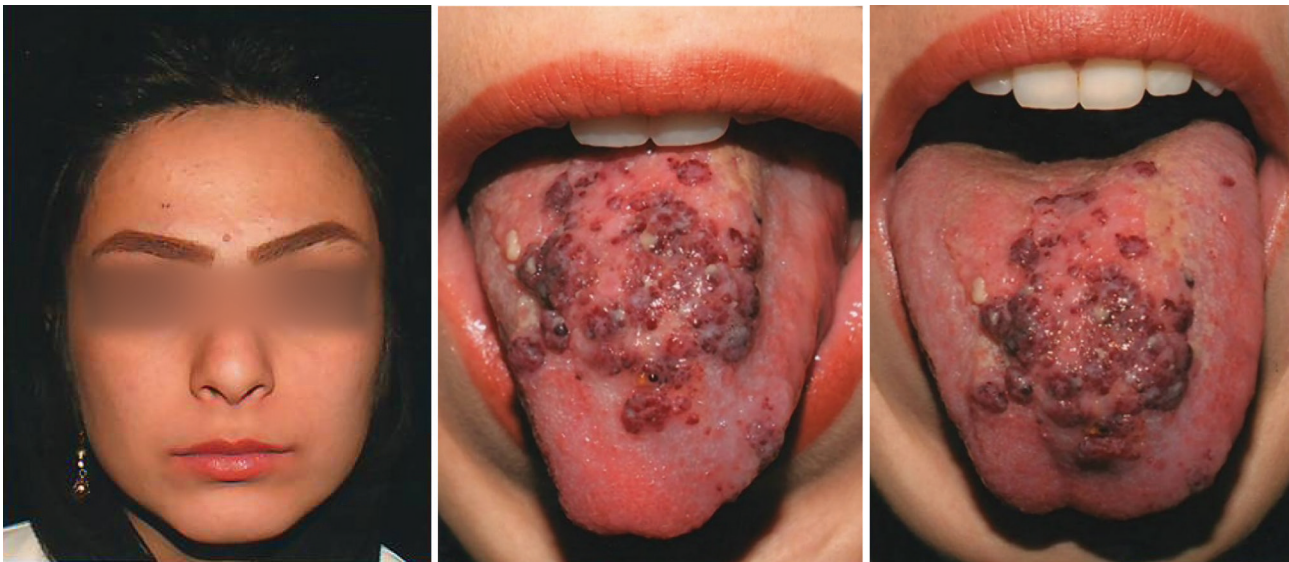

Figure 1. Lymphangioma lesions on the tongue of the 18-year-old patient.

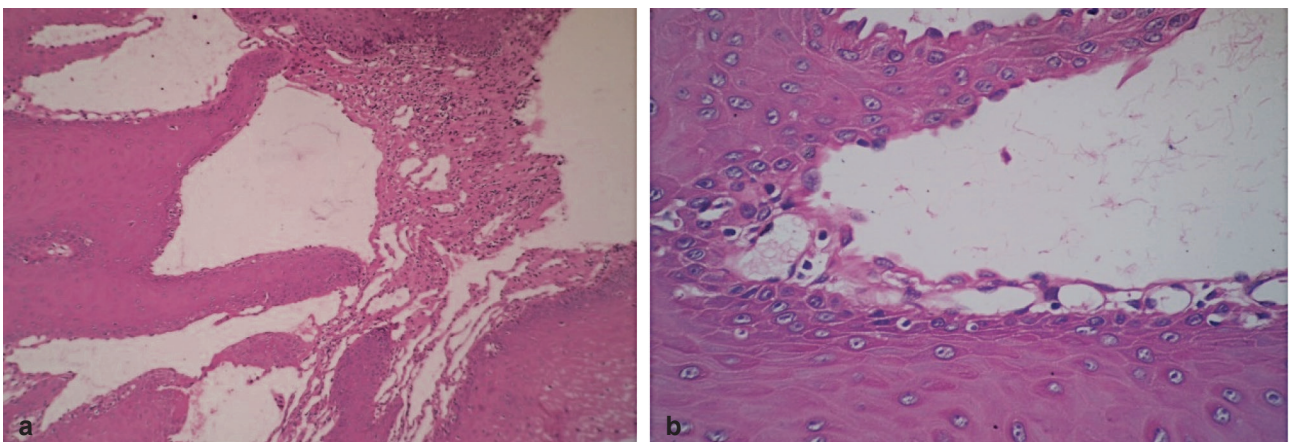


Figure 2. No extensive squamous lymphatic sections with endothelial epithelium plump cells or evidence of malignancy were observed in the biopsy, confirming the diagnosis of lymphangioma.

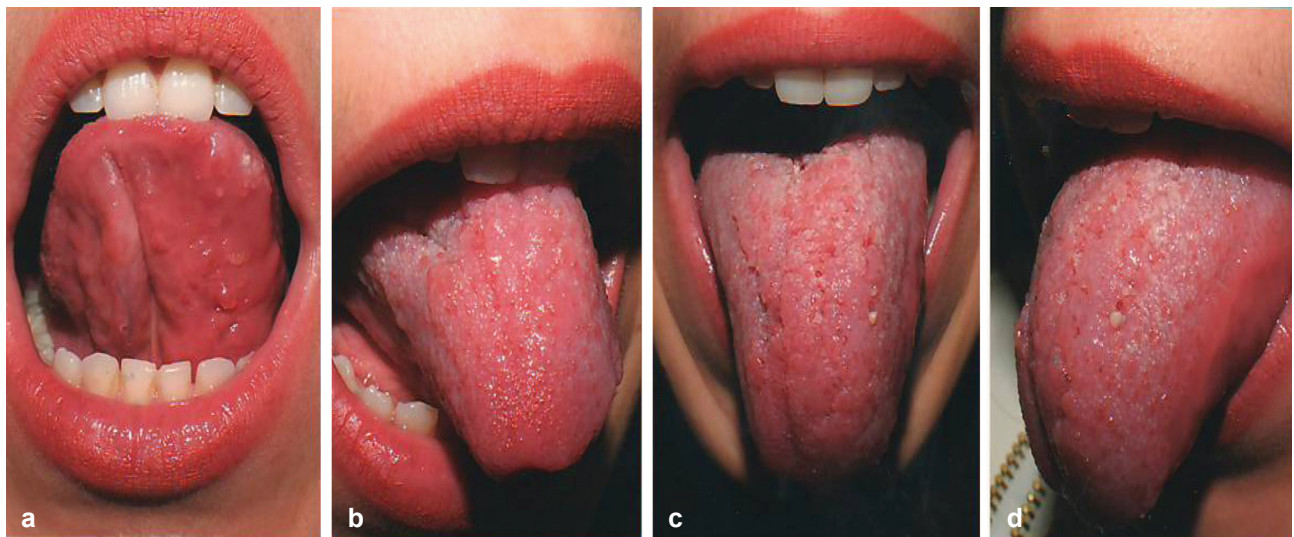


Figure 3. Recovery from the lesion after three sessions of long-pulse Nd:YAG laser therapy. The patient's follow-up after one year revealed no evidence of recurrence.

the use of PDL.

After that, she underwent three sessions of long-pulsed Nd:YAG laser therapy (Dueeto Company, Italy, 2016). Her tongue was anesthetized using xylocaine spray in each session before applying the laser. The handpiece, fluency, and pulse width were 5 mm, 11 J/cm², and 30 ms, respectively. The administered shot numbers were 33, 30, and 31 for the first, second, and third laser therapy sessions, respectively. The patient underwent weekly follow-up visits, and the lesion was photographed in each session, revealing a dramatic response to the treatment within three sessions (Figure 3).

DISCUSSION

Lymphangioma is the most common type of microcystic lymphatic malformation, considered in the category of hamartomas and congenital abnormalities of the lymphatic system⁴. Surgical removal, cryotherapy, electrocoagulation, and laser therapy are the modalities of choice for treating lymphangiomas. Although surgical removal is a valid option, it is invasive with probable complications, such as the increased risk of bleeding, infection, incomplete response, and dyspnea. Furthermore, numerous relapses have been reported following this method⁶.

This study reviewed the treatment of cutaneous and mucosal lymphangiomas with laser therapy (Table 1), revealing an association with side effects

such as bleeding and edema without serious and dangerous complications. Most previous research has dealt with recurrence. In this study, recurrence was either absent or low, and laser therapy interrupted the lymphatic drainage of the lesions. Some articles have reported scar-like tissue instead of lymphangioma. Most studies have focused on ablative lasers, especially CO₂ and Erbium YAG, and less focus has been on the destruction of mucosal lymphangiomas using non-ablative lasers. Currently, given that many laser fields tend to examine the therapeutic dimensions of non-ablative lasers possibly associated with shorter recovery periods, more information about mucosal lymphangiomas is also critical. The long-pulsed Nd:YAG laser is rarely used for destroying mucosal lymphangiomas. It has only been examined in the genital mucosa. Since there is no similar study on the tongue mucosa, our case was the first lymphangioma of the tongue to be treated with this type of non-ablative laser. In Ryosuke Sasaki's study, ablation laser (CO₂) was compared with non-ablation laser (long-pulsed Nd:YAG) to treat vulvar lymphangioma. Sides treated with the non-ablation laser improved in fewer sessions, and lymphatic drainage was completely stopped after each session, whereas lymphatic drainage temporarily increased with the ablation laser. Patients were also more satisfied with the non-ablation laser⁷.

In our case, however, PDL did not lead to an

Table 1. Evaluation and comparison of different types of lasers in the treatment of mucosal and cutaneous lymphangiomas

Author	Sex/age	Past medical history	Location (size)	Previous intervention	Type of laser	Session (interval)	Follow-up	Outcome Recurrence Adverse effects
Amanda Vieira Aires et al. (2020) ¹²	M/9 years	Nil	Dorsum of the tongue (3 cm ²)	Nil	Gallium-indium-arsenide diode laser (808 nm)	2 (90 days)	3, 6, and 12 months	- After a year, a US exam in the area of the lesion revealed fibrotic tissue rather than microcystic lymphangioma. - No recurrence. - Edema and difficulty chewing 2 days after the first session. - A secondary tongue infection caused by poor oral hygiene. - Minimal bleeding, pain, and edema.
Dietmar Schulz et al. (2018) ¹³	M/55 years	Treated squamous cell carcinoma of the penis by radical penectomy	Scrotum	Nil	CO ₂ laser (10,600 nm)	4 (N/M)	N/M	- Just white scar-like lesions remained evident after treatment, indicating a positive outcome.
Joy Makdissi et al. (2017) ¹⁴	F/51 years	Treated squamous cell carcinoma of the cervix	Labia majora	Nil	Fractional ablative erbium: yttriumaluminum garnet (YAG) laser (2,940 nm)	1	7 months	- The patient intends to return every 6 months in the future, and if there is a significant recurrence, she wants to get laser therapy again. - No recurrence of fluid leakage and infections.
TL Tompson et al. (2016) ¹⁵	M/4 months	Nil	Supraglottic	Nil	CO ₂ laser spot welding technique applied after glottoplasty	1	6 months	- Supraglottic edema and obstruction increased, stridor decreased, feeding improved, and cyanosis disappeared.
Sandeep Saluja et al. (2015) ¹⁶	F/27 years	Klippel-Trenaunay Syndrome (KTS)	Right anterior and lateral thigh	Nil	Fractional CO ₂ laser (10,600 nm)	1	6 months	- After treatment, fluid drainage ceased. - After 6 months, the lesions are still asymptomatic. - Despite apparent improvement, the possibility of recurrence exists. - No significant pain or downtime.
Sara Flores et al. (2014) ¹⁷	F/17 years	Nil	Right shoulder (16x10 cm ²)	Nil	Pulsed-dye laser (PDL) (585 nm)	4 (30 days for first three sessions, 60 days for last session)	-	- After 1 session, there was a marked improvement in the inferior part of the lesion. - Complete resolution reached after 4 sessions. - Mild hyperpigmentation and hypopigmentation were seen, which faded over time.
Ryosuke Sasaki et al. (2014) ⁷	F/16 years	Nil	Vulva (10 cm)	Nil	Right-sided vulvar lesion: CO ₂ laser (10,600 nm) Left-sided lesion: long-pulsed Nd:YAG laser (1064 nm)	4 (30 days)	2 years	- After 4 sessions, the right side significantly improved, with no visible lesions. After just 3 sessions, the left side improved. Since lymphatic fluid discharge was temporarily increased (for 1 week) after each CO ₂ laser irradiation but ceased after Nd:YAG, the patient favored the Nd:YAG laser results. - No recurrence after 1 year.
Peter R. Shumaker, et al. (2013) ¹⁸	M/7 years	Nil	Neck (2x1.5 cm ²)	Nil	Fractional CO ₂ laser (10,600 nm)	2 (30 day)	6 months	- After 1 month, no fluid leakage was observed. - After 6 months, clinical and subjective improvements were observed without signs of scar or pigment changes. 1- 2 mm foci of possible persistence or recurrence were observed. - No significant pain, downtime, or visible scarring.

Table 1. Continued

Author	Sex/age	Past medical history	Location (size)	Previous intervention	Type of laser	Session (Interval)	Follow-up	Outcome Recurrence Adverse effects
Luis Antonr, et al (2013) ¹⁹	F/18 years	Nil	Tongue	Nil	Fractional CO ₂ laser	8 (30 day)	12 months	- Excellent cosmetic outcome. - No recurrence. - No bleeding, perforation, or scarring was observed.
Katerina Tsilika, et al (2013) ²⁰	M/13 years	Nil	Right arm	surgical treatment	Fractional ablative erbium laser (2940 nm)	2 (60 day)	2, 6, and 18 months.	- The epidermis was completely free of vesicles, but the superficial dermis had residual lesions, according to reflectance confocal microscopy (RCM). - No recurrence after 18 months of follow- up. - Only moderate pain during the session. - Transient erythema and crusting noted in the first week after the sessions.
Paolo Fioramonti (2013) ²¹	F/25 years	N/M	Right gluteal region	N/M	Sclerotherapy, surgery and laser therapy (pulsed dye laser (PDL) / erbium: yttrium–aluminum-garnet (YAG))	6 (21-28 day)	3 years	- All lesions were removed. After the last session, the treated area was eutrophic and uniform in color. - In touch, it was smooth and soft. - No recurrence.
EsmeeLanjou, et al (2011) ²²	M/43 years	Bilateral varicose veins	Scrotum (8×13 cm ²)	Nil	CO ₂ laser ablation	6 (28-35 day)	12 months	- After 4 sessions, lymphorrhea ceased. - Minor local recurrences in some treated areas. - A few hypopigmented spots and signs of scarring were observed after the last session.
AhmetArsian, et al (2011) ²³	F/63 years	Nil	Gingiva of the mandibular alveolar bone(1.5 cm)	Nil	Fractional CO ₂ laser (10,600 nm)	1	2 years	- With its hemostatic effect, the CO ₂ laser worked well during the excision. - No recurrence after 2 years of follow- up.
Samir Nammour, et al (2016) ²⁴	F/38 years	N/M	Tongue	electrocoagulation, excisions, radiotherapy, cryotherapy, sclerotherapy, drainages	Fractional CO ₂ laser (10,600 nm)	5 (N/M)	10-20 years	- Patients' function improved. - No recurrence after 10–20 years of follow- up.
Shyamala C et al. (2002) case series ²⁵	F/27 years F/35 years	N/M	Vulvar	N/M	CO ₂ laser	N/M	31 months for 27-year-old patient and 11 months for 35-year-old patient	- In both patients, complete healing with re-epithelialization and resolution of postoperative pain and swelling took less than a month. - At 31 months, there was a focal recurrence in the 27- year- old patient, as well as persistence in the 35- year- old patient.

Abbreviations: N/M, not mentioned; CO₂ laser, carbon dioxide laser.

acceptable response, so satisfactory outcomes were achieved after three Nd:YAG laser therapy sessions. PDL is designed to recover and repair vascular skin lesions that pass over the skin surface layers without impacting the capillaries lying on the deep layers⁸. Therefore, we administered a long-pulsed Nd:YAG laser instead, which is absorbed by hemoglobin, melanin, and water, to treat deep to severe dermal lesions, such as bleeding vascular malformations. Nevertheless, Sasaki *et al.* asserted that the device configuration and endpoint settings should be determined based on the physician's experience and type of lesion⁷. For instance, Coelho *et al.* administered 50 ms of fluence with 130 J/cm² pulse, more than 11-folds higher than ours. This high-energy treatment is the probable reason for their patient's response to the treatment in the first session⁹. Medeiros conducted a case series on 15 patients with oral vascular malformations and achieved reasonable outcomes with minimal complications using Nd:YAG laser with a fluence of 2.075 J/cm² and a power density of 268.57 W/cm². Most of the patients responded well with only a session except one who required three laser therapy sessions¹⁰. Similar promising outcomes were reported by Bastos *et al.* in the treatment of a lip vascular lesion using long-pulsed Nd:YAG laser¹¹.

In Table 1, we have summarized data evaluating and comparing different types of lasers in treating mucosal and cutaneous lymphangiomas^{7,12-25}. Laser therapy such as Er:YAG laser, CO₂ laser, and PDL can be used as low-recurrence treatments for cutaneous and mucosal lymphangiomas according to studies published from 2010 to date. Nammour *et al.* used the CO₂ laser in one of the studies for 17 patients with diffuse and unexcisable lymphangiomas of the oral cavity. After 20 years of follow-up, there was localized recurrence in three cases. The recurrent areas were successfully re-treated with the same technique, and no further recurrence occurred²⁴.

Given the observations made in the case of this report, the long-pulsed Nd:YAG laser can treat and resolve lymphangioma lesions over a limited number of sessions, averting the need for surgical removal. Different types of ablative or non-ablative lasers have been used for various kinds of dermatologic indications, especially scars²⁶⁻³⁰. However, the indications of ablative or

non-ablative lasers for other disorders are rapidly growing considering the targeted and selective destruction achieved, as seen in this study.

CONCLUSION

Treatment of lymphangioma varies per case. Laser therapy can be used as a successful and low-recurrence treatment for lymphangiomas. It has few side effects, but the complications observed are not life-threatening and can be resolved quickly, especially with non-ablative lasers. Non-ablative laser treatment of lymphangioma requires fewer sessions and has fewer side effects than ablative laser treatment, making it a promising subject for further research. Laser therapy is a generally safe and effective treatment modality, with optimal outcomes possible after two to four sessions across thirty-day intervals.

Acknowledgment

The authors would like to thank the Rasool Akram Medical Complex Clinical Research Development Center (RCRDC) for its technical and editorial assistance.

Conflict of Interests: None declared.

Data availability

The data supporting the findings of this study are available from the corresponding author upon reasonable request.

REFERENCES

1. Patel GA, Siperstein RD, Ragi G, et al. Zosteriform lymphangioma circumscriptum. *Acta Dermatovenerol Alp Panonica Adriat.* 2009;18(4):179-82.
2. Amini Z, Ansari H, Zarei M, et al. Comparison of communication skills, problem solving skills, self-awareness, decision making skills, and family health among substance addicts and healthy people in Isfahan city, Iran, 2017. *J Isfahan Medi Sch.* 2018;36(483):680-6.
3. Brennan TD, Miller AS, Chen S-Y. Lymphangiomas of the oral cavity: a clinicopathologic, immunohistochemical, and electron-microscopic study. *J Oral Maxillofac Surg.* 1997;55(9):932-5.
4. Morley S, Ramesar K, Macleod D. Cystic hygroma in an adult: a case report. *J R Coll Surg Edinb.* 1999;44(1):57-8.

5. Browse N, Whimster I, Stewart G, et al. Surgical management of 'lymphangiomas circumscriptum'. *Br J Surg.* 1986;73(7):585-8.
6. Roy K, Agarwal R, Agarwal S, et al. Recurrent vulval congenital lymphangioma circumscriptum—a case report and literature review. *Int J Gynecol Cancer.* 2006;16(2):930-4.
7. Sasaki R, Negishi K, Akita H, et al. Successful treatment of congenital lymphangioma circumscriptum of the vulva with CO₂ and long-pulsed Nd: YAG lasers. *Case Rep Dermatol.* 2014;6(1):1-4.
8. Emer J, Gropper J, Gallitano S, et al. A case of lymphangiomas circumscriptum successfully treated with electrodesiccation following failure of pulsed dye laser. *Dermatol Online J.* 2013;19(3):2.
9. Dias Coelho J, Serrao V. Treatment of vascular lesions of the tongue with Nd: YAG laser. *Case Rep Med.* 2009;2009:795363.
10. Medeiros Jr R, Silva IH, Carvalho AT, et al. Nd: YAG laser photocoagulation of benign oral vascular lesions: a case series. *Lasers Med Sci.* 2015;30(8):2215-20.
11. Bastos JT, Balassiano LKdA, Mariano da Rocha CR, et al. Treatment of vascular lesions located in the lip and in the oral cavity with Nd: YAG laser. *J Cosmet Laser Ther.* 2017;19(5):256-8.
12. Aires AV, Kato CNAO, Silva LVO, et al. Lingual lymphangioma ablation with high power diode laser: A case report. *J Lasers Med Sci.* 2020;11(2):234-7.
13. Schulz D, Lein A, Nicula AP, et al. Lymphangioma circumscriptum post radiotherapy for penile cancer treated with CO₂ laser. *Acta Dermatovenerol Croat.* 2018;26(1):53-7.
14. Makdisi J, de Feraudy S, Zachary CB. Vulvar Lymphangioma Circumscriptum Treated With Fractional Ablative Erbium: Yttrium Aluminium Garnet Laser. *Dermatol Surg.* 2018;44(8):1149-51.
15. Thompson TL, Gungor A. Diffuse, encasing lymphangioma of the supraglottis. *Am J Otolaryngol.* 2016;37(1):41-3.
16. Saluja S, Petersen M, Summers E. Fractional carbon dioxide laser ablation for the treatment of microcystic lymphatic malformations (lymphangioma circumscriptum) in an adult patient with Klippel-Trenaunay syndrome. *Lasers Surg Med.* 2015;47(7):539-41.
17. Flores S, Baum C, Tollefson M, et al. Pulsed dye laser for the treatment of acquired progressive lymphangioma. *Dermatol Surg.* 2014;40(2):218-21.
18. Shumaker PR, Dela Rosa KM, Krakowski AC. Treatment of lymphangioma circumscriptum using fractional carbon dioxide laser ablation. *Pediatr Dermatol.* 2013;30(5):584-6.
19. Torezan LA, Festa-Neto C. Intra-oral lymphangioma successfully treated using fractional carbon dioxide laser. *Dermatol Surg.* 2013;39(5):816-7.
20. Tsilika K, Bahadoran P, Passeron T. Superficial lymphangioma treated with fractional ablative laser: a case report with clinical and reflectance confocal microscopy evaluation. *Dermatol Surg.* 2013;39(1 Pt 1):141-3.
21. Fioramonti P, Maruccia M, Ruggieri M, et al. A rare case of lymphangioma in the gluteal region: surgical treatment combined with sclerotherapy and laser therapy. *Aesthetic Plast Surg.* 2013;37(5):960-4.
22. Lanjouw E, de Roos KP, den Hollander JC, et al. Acquired scrotal lymphangioma successfully treated using carbon dioxide laser ablation. *Dermatol Surg.* 2011;37(4):539-42.
23. Arslan A, Gursoy H, Cologlu S. Treatment of lymphangioma with CO₂ laser in the mandibular alveolar mucosa. *J Contemp Dent Pract.* 2011;12(6):493-6.
24. Nammour S, Vanheusden A, Namour A, et al. Evaluation of a new method for the treatment of invasive, diffuse, and unexcisable lymphangiomas of the oral cavity with defocus CO₂ laser beam: A 20-year follow-up. *Photomed Laser Surg.* 2016;34(2):82-7.
25. Huilgol SC, Neill S, Barlow RJ. CO₂ laser therapy of vulval lymphangiectasia and lymphangioma circumscriptum. *Dermatol Surg.* 2002;28(7):575-7.
26. Behrangi E, Goodarzi A, Roohaninasab M, et al. A review of scar treatment related to acne and burn. *J Crit Rev.* 2020;7(4):714-22.
27. Goodarzi A, Behrangi E, Ghassemi M, et al. Acne scar; a review of classification and treatment. *J Crit Rev.* 2020;7(7):1108-14.
28. Mehran G, Fotooei M, Goodarzi A, et al. Comparison of the therapeutic effect of microneedling with carbon dioxide laser in hypertrophic burn scars: a randomized clinical trial. *Iran J Dermatol.* 2019;22(2):53-7.
29. Goodarzi A. Non-medical treatments for inflammatory acne vulgaris: a comprehensive review on laser, radiofrequency and microneedling. *Iran J Dermatol.* 2019;22(3):97-106.
30. Seirafianpour F, Sodagar S, Mozafarpoor S, et al. Systematic review of single and combined treatments for different types of striae: A comparison of striae treatments. *J Eur Acad Dermatol Venereol.* 2021 May 22.