

Recalcitrant giant orf recurrence after amputation: A case report and review of the literature

Vahide Saeidi¹  | Elahe Aminizade¹  | Yasamin Kalantari^{2,3}  |
Azadeh Goodarzi^{4,5} 

¹Department of Dermatology, Payambar Azam Hospital, Kerman, Iran

²Department of Dermatology, Razi Hospital, Tehran University of Medical Sciences, Tehran, Iran

³Autoimmune Bullous Diseases Research Center, Tehran University of Medical Sciences, Tehran, Iran

⁴Department of Dermatology, Rasool Akram Medical Complex Clinical Research Development Center (RCRDC), School of Medicine, Iran University of Medical Sciences, Tehran, Iran

⁵Skin and Stem Cell Research Center, Tehran University of Medical Sciences, Tehran, Iran

Correspondence

Azadeh Goodarzi, Department of Dermatology, Rasool Akram Medical Complex Clinical Research Development Center (RCRDC), School of Medicine, Iran University of Medical Sciences, Tehran, Iran.

Emails: azadeh_goodarzi1984@yahoo.com; goodarzi.a@iums.ac.ir

Abstract

Orf is caused by a parapoxvirus. We present a recurrent, giant digital orf case in a female patient with a history of hairy cell leukemia. In spite of shave excision, the lesion progressed and recurred after digital amputation. Treatment with topical imiquimod cream and systemic subcutaneous interferon alfa-2a was successful.

KEYWORDS

amputation, ecthyma contagiosum, imiquimod, immunocompromised, interferon alfa-2a, nodule, orf, poxvirus, recalcitrant, resistant, review, tumor

1 | INTRODUCTION

Ecthyma contagiosum, also called the orf disease, is a zoonotic skin infection caused by the orf virus (OrfV) that belongs to the family of *parapoxvirus*. It is transmitted to humans by direct contact with infected animals (such as sheep and goats) or by contaminated fomites and meat.¹

It is a self-limiting condition in immunocompetent patients and typically resolves after several weeks without any specific treatment. However, in immunocompromised patients such as cases with a history of organ transplant, orf usually manifests as giant, persistent and atypical lesions.²⁻⁵

Herein, we present a case of recurrent, giant digital orf in a female patient with a past medical history of hairy cell

This is an open access article under the terms of the [Creative Commons Attribution-NonCommercial-NoDerivs](https://creativecommons.org/licenses/by-nc-nd/4.0/) License, which permits use and distribution in any medium, provided the original work is properly cited, the use is non-commercial and no modifications or adaptations are made.

© 2022 The Authors. *Clinical Case Reports* published by John Wiley & Sons Ltd.

leukemia in addition to a literature review on cases of orf in immunocompromised patients.

2 | CASE PRESENTATION

A 70-year-old woman with an enlarging tumor on the dorsum of her right second finger presented to our clinic. She had been diagnosed with hairy cell leukemia 5 years ago. The patient had received rituximab and cladribine and was in complete remission. At the present time, she was not receiving any treatment for hairy cell leukemia. She had a history of cutting her finger while cleaning and preparing a sheep's head and one week later, a non-healing lesion developed on her right second finger. Four months after the lesion's appearance, she visited a surgeon. The lesion was removed with a shave excision, and the pathology reported it as granulation tissue. One month later, a rapidly growing, lobulated mass recurred at the site of the shaved biopsy, which grew to approximately 6x10 cm after several weeks (Figure 1). She visited a family medicine physician and was referred to a surgeon for an incisional biopsy to rule out possible malignancies. However, during the operation, the surgeon decided to amputate the digit due to the broad base of the tumor and tissue fragility and sent it to a pathology laboratory. The histopathologic examination revealed

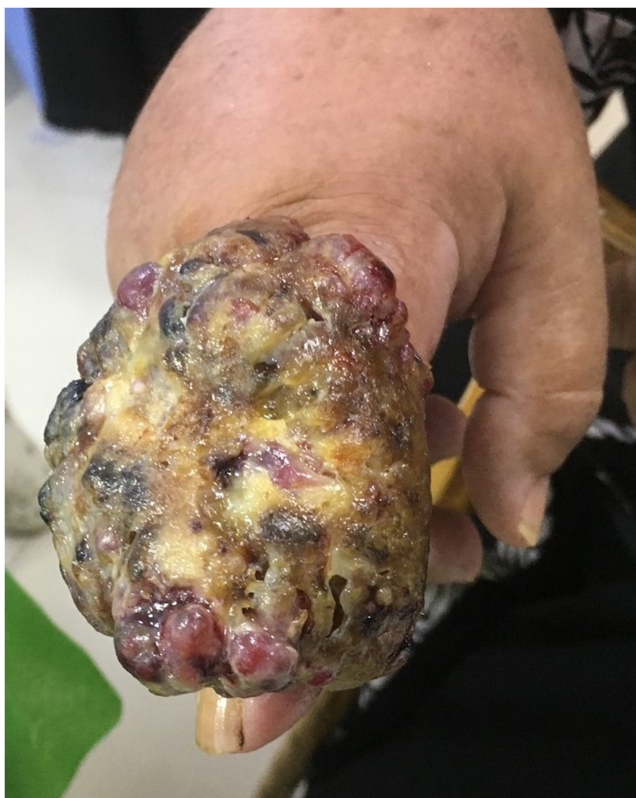

FIGURE 1 Giant orf lesion on the dorsum of the index finger of the right hand

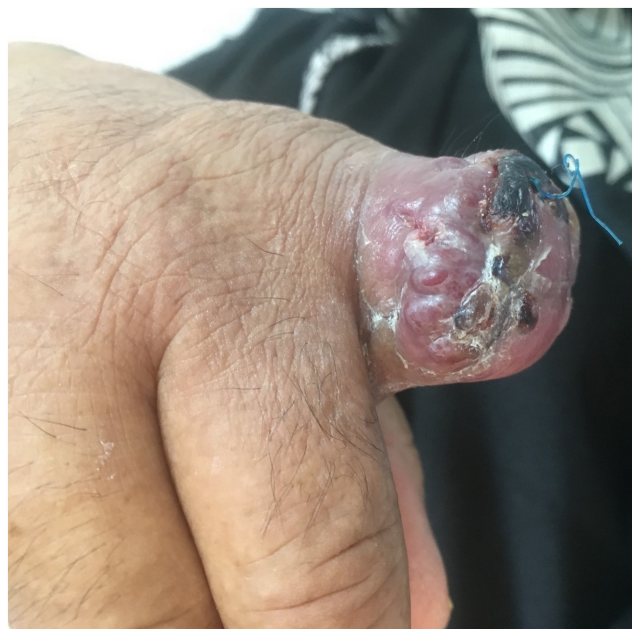

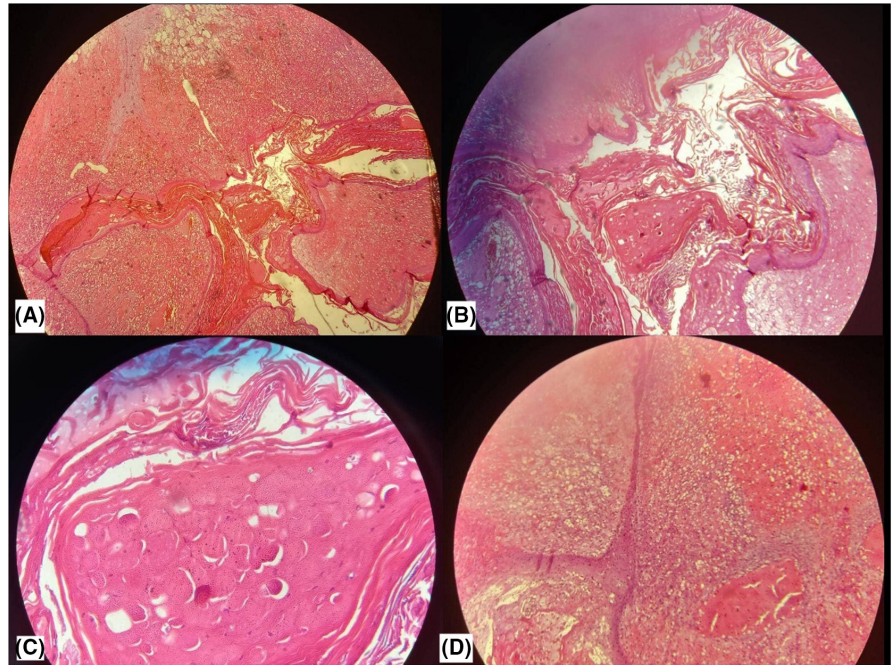
FIGURE 2 Orf lesion recurred after 2 weeks following the amputation

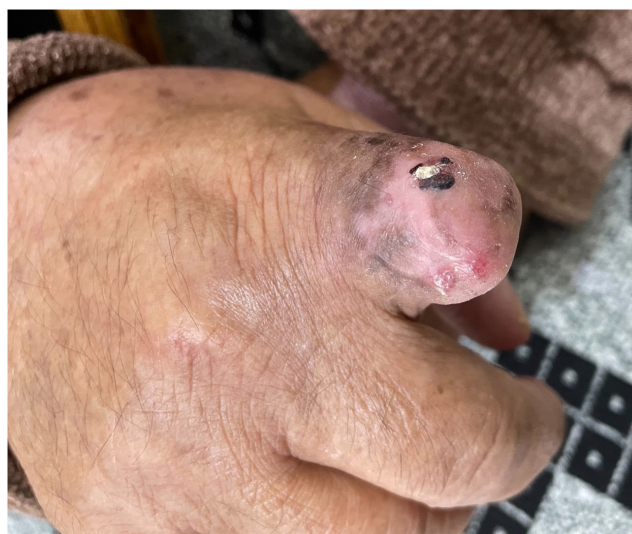

FIGURE 3 Complete resolution after 10 weeks of treatment with subcutaneous injections of interferon alfa-2a and topical imiquimod cream 5%

vacuolated epidermal cells with eosinophilic inclusion bodies in some keratinocytes (Figure 4). The pathology result in addition to the patient's history of the previous contact with sheep was consistent with the diagnosis of orf disease. Two weeks after the surgery, signs of recurrence were noticed, and the patient was referred to a dermatologist (Figure 2). Recurrent lesions were treated with cryotherapy (every two weeks) and topical imiquimod cream (three times a week). Despite treatment with topical imiquimod cream

FIGURE 4 A–D: H&E staining revealed island spaces formed by finger-like downward projections of epidermis. Epidermis & projections composed of vacuolated epidermal cells with some eosinophilic bodies. No malignant change was identified. Hyperplasia, parakeratosis, stroma with hyper-vascularization, acanthosis, and viral inclusions of Orf were observed



and two sessions of cryotherapy, the lesions enlarged after one month, and new lesions began to appear at the site of the amputation. She was prescribed systemic subcutaneous injections of interferon alfa-2a (3 million IU twice weekly) and topical imiquimod cream 5% daily. Treatment was well tolerated by the patient with no complications except for a mild fever the first night after each injection. Four weeks after starting the interferon, remarkable shrinkage of lesions was observed. As a result, the interferon injections were reduced to 3 million IU weekly and continued for 6 more weeks when all lesions were resolved (Figure 3). No new lesions were noted during the six months of follow-up.

3 | DISCUSSION

We reviewed the literature in PubMed/Medline database for articles published from inception up to 2/8/2022 regarding cases of orf in immunocompromised patients by using the following keywords:

Orf, contagious pustular dermatitis, contagious ecthyma, infectious labial dermatitis, ecthyma contagiosum, thistle disease, scabby mouth, immunosuppressed, immunosuppression, immunocompromised, immunocompromised, immuno-suppressed, immunocompetent.

Out of the retrieved articles, we included 14 studies. Twelve (85.71%) males and two (14.28%) females with a mean age of 52.5 ± 11.31 were enrolled. The majority of patients ($n = 8$, 57.14%) had a history of organ transplants and most of them had a history of contact with sheep. The characteristics of the included studies are summarized in Table 1.

Human orf is a self-limited skin infection caused by a *parapoxvirus* and transmitted to humans through contact with infected animals such as sheep and goats or contaminated fomite. The virus from infected animals is proposed to transmit to human skin by cuts and abrasions. Orf lesions are most frequently found on the exposed areas of the human skin that can be in contact with animals. Orf lesions can be painful. Notably, secondary bacterial infections can occur at the site of skin openings.²¹ Orf lesions usually regress and heal spontaneously in 3–6 weeks with no scarring.^{1,2} Previous studies indicated that Orf in humans can be misdiagnosed and they are mostly overtreated with undesired high costs.²¹ There has not been any report of mortality from Orf in humans.^{21–25}

However, in immunocompromised patients, the lesions may be giant (tumor-like), long-lasting, and resistant to treatment.³ Amputation should only be considered as the last chance remedy in severe cases with no response to treatment.^{21,26–28} Histological findings include epithelial hyperplasia, intracellular viral inclusions, and prominent dermal vasculature. It should be noted that these findings are nonspecific, and a definite diagnosis can be made by PCR.⁴

Opene et al. proposed the name “orf progressiva” to describe the destructive and progressive nature of this type of giant orf and its resistance to treatment.⁵

Treatment options considered for giant orf in immunocompromised patients often include surgical excision,⁶ cryotherapy, topical imiquimod,^{7,8} topical idoxuridine 40% application,⁹ topical and intralesional cidofovir,¹⁰ intralesional and systemic interferon injection.^{11,12}

TABLE 1 Characteristics of the included studies

First author and year of publication	Gender and age (years)	Past medical history	Lesion type	Source	Treatment	Results
Opene, 2021	Male, 43	Kidney transplant 3 years ago	Friable fungating mass	Lamb	Topical imiquimod, oral valacyclovir	Complete resolution of lesion
Harms, 2019	Male, 48	Liver transplant	Exophytic, ulcerated tumor with hemorrhagic oozing	Lamb	Shave removal was performed, and the base was cauterized. Topical imiquimod	Complete resolution of lesion
Kostopoulos, 2018	Male, 65	Rheumatoid arthritis (RA)	Erythematous nodules that exhibited spontaneous outflow of serous fluid.	Sheep	Surgical debridement, immunosuppressive drugs were discontinued except methylprednisolone	Improvement of lesions after 10 days.
Polivka, 2017	Female, 58	Cadaveric kidney transplant	Tumor-like lesion	N/A	Valaciclovir (3 g/day) and imiquimod (once a day for 5 days a week) and a two-fold reduction in the dose of immunosuppressive drugs (tacrolimus 4 mg. day and mycophenolate mofetil 500 mg/day) had no effects. Weekly open-spray cryotherapy (one cycle: 200s)	Complete regression of lesions
Ertekin, 2017	Male, 68	Chronic lymphocytic leukemia (CLL)	Exophytic, pinkish gray, weeping nodule	Sheep	Surgical removal, oral valacyclovir (1 g 3 times daily) and imiquimod cream 5% (3 times weekly), intralesional interferon alfa-2a injections (3 million IU twice weekly), systemic subcutaneous injections of interferon alfa-2a (3 million IU twice weekly)	Complete resolution
Rørdam, 2013	Male, 45	psoriatic arthritis	tumor	Sheep	surgical removal, cryotherapy (liquid nitrogen), with a freezing time of 30s, applied twice. Etanercept was discontinued, imiquimod on a daily basis	Significant improvement
Zaharia, 2010	Male, 61	kidney transplant	Tumor-like lesion	Sheep	immunosuppressive treatment was decreased, local treatment of orf with imiquimod 5% cream was started.	Complete healing was obtained 6 weeks later
Ara, 2008	Male, 66	kidney transplant	Initially papule that developed into tumoral lesion	Sheep	topical imiquimod 5% cream 3 times per week.	Complete resolution after 16 weeks
Geerinck, 2001	Female, 39	renal transplant	Nodule that then enlarged to a large exophytic lesion	Sheep	cidofovir cream,	Significant improvement
Degraevea, 1999	Male, 48	renal transplantation	nodule	Mutton	Excision, topical idoxuridine, Cryotherapy was started using the open spray technique (2 cycles of 60s initially) with an interval of 1 week	complete regression

TABLE 1 (Continued)

First author and year of publication	Gender and age (years)	Past medical history	Lesion type	Source	Treatment	Results
Peeters, 1998	Male, 44	renal transplantation	Hypertrophic lesion with central necrosis at the right thumb	Lamb	Topical idoxuridine 40%, cryotherapy	complete regression
Tan, 1991	Male, 30	Nezelof's syndrome	Tumor-like lesion	Sheep	Excision, 40% idoxuridine, Daily intralesional injections of a-interferon (1 X 10 ⁶ units per lesion), A course of transfer factor harvested from the white cells of his brother, amputation	Improvement of the lesion
Savage, 1972	Male, 65	Lymphoma	Tumor-like lesion	Sheep	amputation	Improvement of the lesion
hunskaar, 1986	Male, 55	chronic lymphocytic leukemia	Initially an ulcer that developed into nodule.	Sheep	topical idoxuridine	Improvement after 14 days
Saeidi, 2022 (Current case)	Female, 70	hairy cell leukemia	Enlarging tumor	sheep	Shave excision, digital amputation, topical imiquimod cream, and systemic subcutaneous interferon alfa-2a	Successful treatment

Surgical strategies often cause a delay in the healing process with a high rate of recurrence. In some cases, giant orf lesions are misdiagnosed as skin cancers and lead to amputation.⁴ Therefore, physicians must be aware of tumor-like presentations of giant orf in immunocompromised patients to avoid aggressive surgical procedures and potential morbidity. Most progressive orf patients, subjected to surgical treatment, require serial excisions or combination medical therapy for complete remission of the condition. Hence, surgical procedures are not recommended as the first line of treatment for these patients. Based on the results of our literature review, the majority of cases that showed large-sized tumor-like lesions of orf had a history of organ transplant.

We observed a complete resolution with systemic interferon alfa-2a injections combined with topical imiquimod in ten weeks. In a similar case reported by Ertekin et al.,¹² this treatment resulted in complete healing in 9 weeks.

The antiviral, antiproliferative, and antiangiogenic properties of systemic interferon alfa-2a result in complete regression of the lesions, making it a suitable option for treatment of recalcitrant giant orf in immunocompromised patients.¹³⁻¹⁷

In conclusion, immunocompromised patients may experience giant, persistent, and atypical lesions of orf disease. Our case highlights the importance of considering orf as a differential diagnosis, especially in immunocompromised patients complaining of a nodule or tumor-like lesions with a past history of close contact with animals such as sheep and goats or a history of cutting a body part through meat cleaning. When facing such lesions, a thorough history including the patient's occupation, close contact with animals, and history of cutting a body part (commonly extremities) should be taken from the patient.¹⁸⁻²⁰ Our case is unique in that it presents a case of recalcitrant orf that persisted even after amputation which was successfully treated with interferon alfa-2a. Before amputation in orf cases, a thorough assessment and consultation with infectious disease specialists, surgeons, and dermatologists should be done. Physicians should be aware of the rare presentation of diseases particularly in immunocompromised patients in order to avoid misdiagnosis.

AUTHOR CONTRIBUTIONS

All authors contributed to the preparation and finalization of this article. VS, EA, YK, and AG contributed to writing the article and study design. YK and AG contributed to literature review. AG, YK contributed to final editing.

ACKNOWLEDGMENTS

The authors would like to express their gratitude to the staff of the Rasool Akram Medical Complex Clinical Research Development Center (RCRDC) for their technical and editorial assistance.

CONFLICT OF INTEREST

None.

DATA AVAILABILITY STATEMENT

Not Applicable.

ETHICAL APPROVAL

This study was approved by the Medical Ethics Committee of our institution.

CONSENT

Written and oral informed consent was obtained from this patient.

ORCID

Vahide Saeidi  <https://orcid.org/0000-0002-9763-2068>

Elahe Aminizade  <https://orcid.org/0000-0002-2322-9989>

Yasamin Kalantari  <https://orcid.org/0000-0001-8443-4591>

[org/0000-0001-8443-4591](https://orcid.org/0000-0001-8443-4591)

Azadeh Goodarzi  <https://orcid.org/0000-0002-1249-4429>

REFERENCES

- Caravaglio JV, Khachemoune A. Orf review with a focus on advances in diagnosis and treatment. *Drugs Dermatol.* 2017;16:684-689.
- Snyder RR, Diven DG. Orf. In: Freedberg IM, Eisen AZ, Wolff K, et al., eds. *Fitzpatrick's Dermatology in Clinical Medicine*. 6th ed. McGraw-Hill; 2003:2110-2114.
- Savage J, Black MN. "Giant" orf of finger in a patient with a lymphoma. *Proc R Soc Med.* 1972;65:766-768.
- Johannessen JV, Krogh HK, Solberg I, Dalen A, van Wijngaarden H, Johansen B. Human orf. *J Cutan Pathol.* 1975;2:265-283.
- Opene C, Fung MA, Silverstein M. Orf progressive: giant progressive and destructive infections in the immunocompromised. *Dermatol Online J.* 2021;27(1):7.
- Ballanger F, Barbarot S, Mollat C, et al. Two giant orf lesions in a heart/lung transplant patient. *Eur J Dermatol.* 2006;16:284-286.
- Zaharia D, Kanitakis J, Pouteil-Noble C, Euvrard S. Rapidly growing orf in a renal transplant recipient: favourable outcome with reduction of immunosuppression and imiquimod. *Transpl Int.* 2010;23:E62-E64.
- Lederman ER, Green GM, DeGroot HE, et al. Progressive ORF virus infection in a patient with lymphoma: successful treatment using imiquimod. *Clin Infect Dis.* 2007;44:e100-e103.
- Tan S, Blake G, Chambers S. Recurrent orf in an immunocompromised host. *British J Plast Surg.* 1991;44:465-467.
- Geerinck K, Lukito G, Snoeck R, et al. A case of human orf in an immunocompromised patient treated successfully with cidofovir cream. *J Med Virol.* 2001;64:543-549.
- Ran M, Lee M, Gong J, Lin Z, Li R. Oral acyclovir and intral-lesional interferon injections for treatment of giant pyogenic granuloma-like lesions in an immunocompromised patient with human orf. *JAMA Dermatol.* 2015;151:1032-1034.
- Ertekin SS, Gürel MS, Erdemir AVT, Leblebici C. Systemic interferon alfa injections for the treatment of a giant orf. *Cutis.* 2017;99:E19-E21.
- Harms J, Swick BL, Wanat KA. Pyogenic granuloma-like orf in a transplant patient treated successfully with excision and imiquimod. *JAAD Case Rep.* 2019;5(6):566-567. doi:10.1016/j.jdc.2019.02.035
- Kostopoulos M, Gerodimos C, Batsila E, Kalinou C, Athanassiou P. Orf disease in a patient with rheumatoid arthritis. *Mediterr J Rheumatol.* 2018;29(2):89-91. doi:10.31138/mjr.29.2.89
- Polivka L, Moguelet P, Meritet JF, Ouali N, Francès C, Senet P. Giant orf tumour in an immunocompromised patient. *J Eur Acad Dermatol Venereol.* 2017;31(12):e515-e516. doi:10.1111/jdv.14361
- Rørdam OM, Grimstad Ø, Spigset O, Ryggen K. Giant orf with prolonged recovery in a patient with psoriatic arthritis treated with etanercept. *Acta Derm Venereol.* 2013;93(4):487-488. doi:10.2340/00015555-1514
- Ara M, Zaballos P, Sánchez M, et al. Giant and recurrent orf virus infection in a renal transplant recipient treated with imiquimod. *J Am Acad Dermatol.* 2008;58(2 suppl):S39-S40. doi:10.1016/j.jaad.2006.04.027
- Degraeve C, De Coninck A, Senneseael J, Roseeuw D. Recurrent contagious ecthyma (Orf) in an immunocompromised host successfully treated with cryotherapy. *Dermatology.* 1999;198(2):162-163. doi:10.1159/000018095
- Peeters P, Sennesael J. Parapoxvirus orf in kidney transplantation. *Nephrol Dial Transplant.* 1998;13(2):531. doi:10.1093/oxfordjournals.ndt.a027869
- Hunnskaar S. Giant orf in a patient with chronic lymphocytic leukaemia. *Br J Dermatol.* 1986;114(5):631-634. doi:10.1111/j.1365-2133.1986.tb04072.x
- Kassa T. A review on human orf: a neglected viral zoonosis. *Res Rep Trop Med.* 2021;8(12):153-172. doi:10.2147/RRTM.S306446
- Uzel M, Sasmaz S, Bakaris S, et al. A viral infection of the hand commonly seen after the feast of sacrifice: human orf (orf of the hand). *Epidemiol Infect.* 2005;133(4):653-657. doi:10.1017/S0950268805003778
- Fleming SB, Wise LM, Mercer AA. Molecular genetic analysis of orf virus: a poxvirus that has adapted to skin. *Viruses* 2015;7(3):1505-1539. doi:10.3390/v7031505
- Zhang K, Liu Y, Kong H, Shang Y, Liu X. Human infection with orf virus from goats in China, 2012. *Vector Borne Zoonotic Dis.* 2014;1(1):365-367. doi:10.1089/vbz.2013.1445
- Rajkomar V, Hannah M, Coulson IH, Owen CM. A case of human to human transmission of orf between mother and child. *Clin Exp Dermatol.* 2016;41(1):6063. doi:10.1111/ced.12697
- Yilmaz K, Goletz S, Pas HH, et al. Clinical and serological characterization of orf-induced immunobullous disease. *JAMA Dermatol.* 2022;158(6):670-674.
- Chauhan SL, Agnihotri D, Batra K, Sharma M, Kumar T, Sindhu N, Jain VK. Detection and therapeutic management of contagious ecthyma (ORF) in a kid.
- Karaali MG, Aksu AE, Polat AK, Gurel MS. Solitary facial lesion of orf: an unusual presentation. *North Clin Istanbul.* 2021;8(6):626.

How to cite this article: Saeidi V, Aminizade E, Kalantari Y, Goodarzi A. Recalcitrant giant orf recurrence after amputation: A case report and review of the literature. *Clin Case Rep.* 2022;10:e06209. doi: [10.1002/ccr3.6209](https://doi.org/10.1002/ccr3.6209)